

Dr Peter Chapman-Smith

Are there specific tissues that have been shown to be damaged by this release of free radicals?

C.Narkowicz

The eyes are very susceptible. The retrolental fibroplasia of premature infants is caused by oxygen. The red cells are very vulnerable simply because they carry a lot of the oxygen and actually produce a lot of the radicals. As for other tissues, brain and marrow and the lungs.

One of the problems is that most of the evidence so far is circumstantial. We can show experimentally that if one gives free radical protecting agents one can reduce the damage but most of the evidence is circumstantial because of the difficulty of actually measuring free radicals in these situations and of showing that there is an increase in free radicals associated with the damage.

It would be interesting to put someone with a 6-glucose phosphate dehydrogenase deficiency into the chamber and see what happens to them. They have a slower rate of free radical inactivation, with a decreased pentose phosphate metabolism. So they might be susceptible to oxidative stress a bit earlier than someone with a fully functional pentose phosphate pathway.

Question

Does microwaved food generate free radicals?

C.Narkowicz

Not that I know of. I do not think it should but food irradiation is known to produce hydroxyl radical which is where a lot of the concern comes from because if those radicals are not scavenged by the antioxidants in the food they can affect the proteins, the vitamins, and really affect the quality of the food. Another thing is that ultrasound is known to produce hydroxyl radicals as well. So there is increasing concern over use of ultrasound, or the excessive use of ultrasound, and of course exposure to radiation. Most of the damage is by free radical mechanisms.

This is an edited transcript of a recording made at a Free Radical Workshop during the joint SPUMS and Royal Hobart Hospital meeting on Hyperbaric and Diving Medicine in November 1988.

Mr Christian Narkowicz, B.Sc.(Hons) is attached to the Department of Medicine, University of Tasmania Clinical School, 43 Collins Street, Hobart, Tasmania 7000, Australia.

IRON, OXYGEN RADICALS AND THE JOINT

Fiona Andrews

Iron has been associated with joint inflammation for a number of years. As long ago as 1674 Hochsletter described an arthritis associated with excessive bleeding in haemophilia patients. This was reproduced in experimental animals by injecting blood into the joints. Later on it was also shown that patients with oral iron overload or haemochromatosis also had iron deposits within the synovial membrane, and this was associated with inflammation of an otherwise normal joint.

Interest in iron and joint inflammation was rekindled by the work of Muirden¹ who showed that iron deposition occurred in the synovial membranes of patients with rheumatoid arthritis. It was speculated that perhaps these iron deposits had some role in the pathogenesis of the disease. This leads us to the question, how does iron deposition arise in the rheumatoid joint?

In normal situations iron is carefully conserved and recycled within the body and very little is lost. But in chronic inflammatory conditions such as rheumatoid arthritis many patients become anaemic. This does not appear to be due to an increased loss of iron but to a sequestering of iron within the reticuloendothelial cells so the iron is not let out back into the recirculating pool. How does this relate to the joint? Ultrastructural studies have shown that the synovium consists of reticuloendothelial like cells and it was proposed that iron deposits, derived from periods of micro bleeding in the joint are sequestered in the reticuloendothelial-like cells of the synovium. In support of this Muirden² found that levels of iron within the synovium correlated with an increased activity of joint inflammation.

So how might iron enhance inflammation in the rheumatoid joints? One theory is that iron is involved in oxidative tissue damage. The environment of the inflamed rheumatoid joint is highly suited to the production of reactive oxygen metabolites such as superoxide, hydrogen peroxide and the hydroxyl radical. The major source of reactive oxygen metabolites are the infiltrating inflammatory phagocytic cells. Phagocytosis induces increased cellular aerobic activity which leads to the formation of relatively unreactive superoxide and water. In the presence of iron however hydroxyl radicals, the most toxic reactive oxygen metabolites can be produced. A further factor that leads to an ideal environment for reactive oxygen metabolite activity is an insufficient reactive oxygen metabolites scavenging ability which has also been demonstrated in the rheumatoid joint.

What evidence have we that reactive oxygen metabolite reactions are occurring in the joint? Several studies have demonstrated the presence of lipid peroxidation prod-

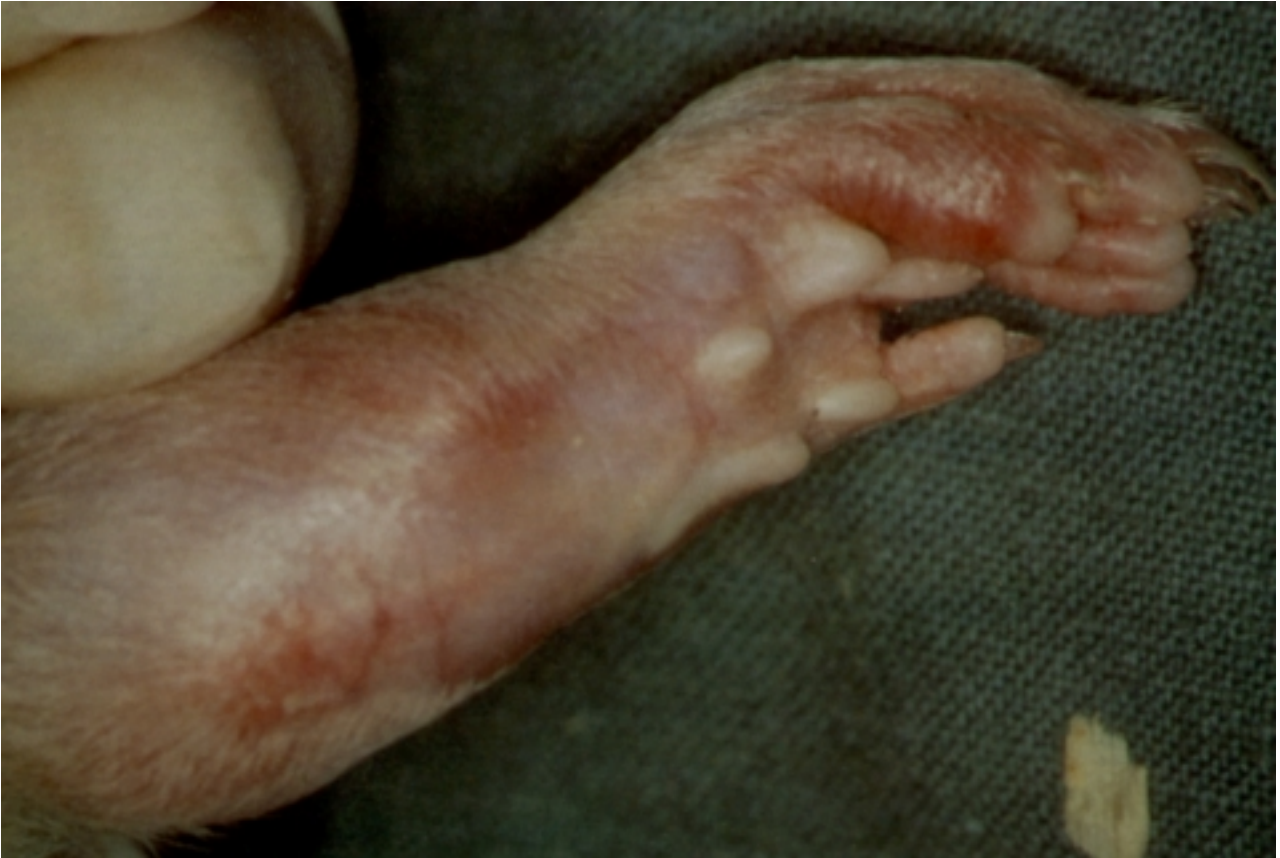

FIGURE 1. A typical arthritic ankle joint from a rat with normal iron levels, 28 days after adjuvant injection showing extensive inflammation.

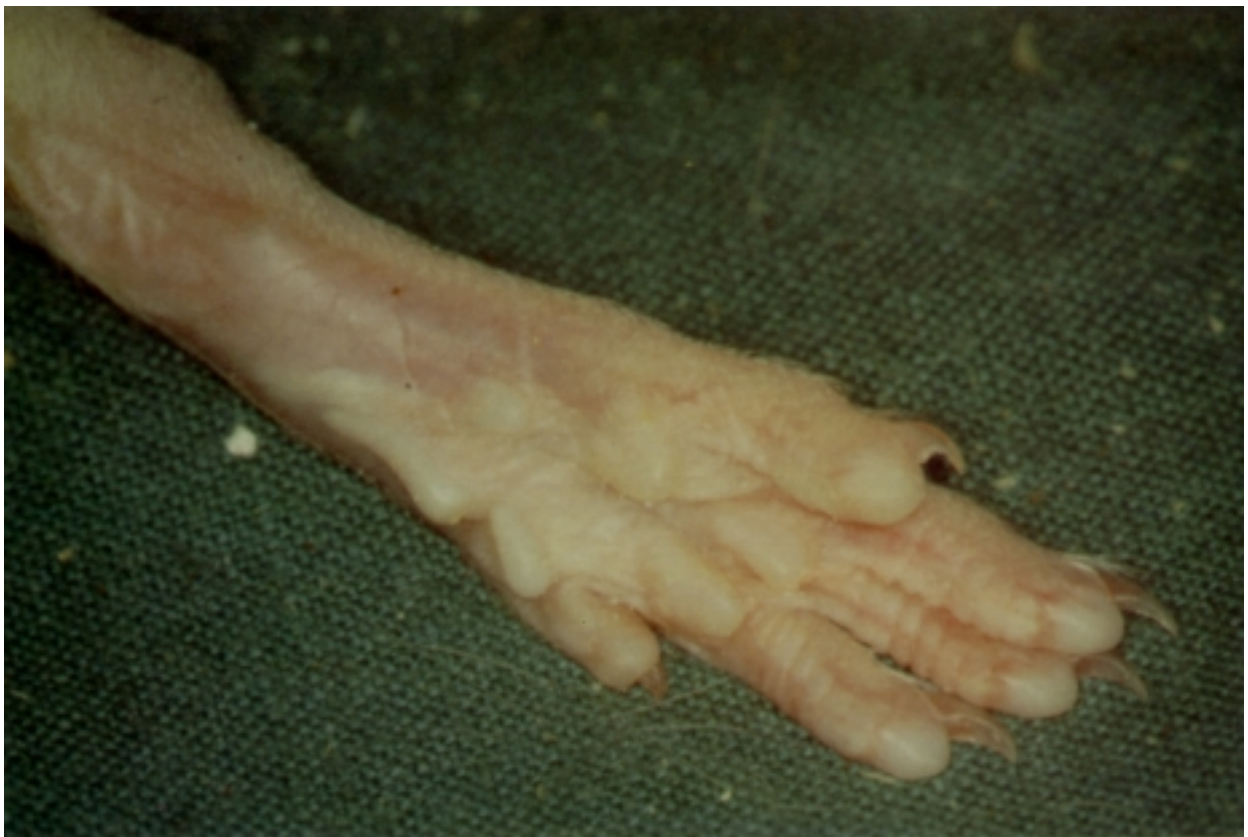

FIGURE 2.
A typical iron deficient rat ankle joint 28 days after adjuvant injection. There is only very mild inflammation.

ucts (products of the reaction of reactive oxygen metabolites and lipid) in rheumatoid joints. Firstly Lunec et al.³ reported that peroxidation products occurred in 90% of rheumatoid synovial fluid samples tested. Wynyard et.al.⁴ found that when rheumatoid patients were infused with iron dextran this led to an exacerbation of synovitis and an increase in lipid peroxidation, suggesting that iron enhanced inflammation via the formation of the hydroxyl radical and its subsequent reaction with cellular lipid.

Based on this evidence, we decided to study this concept further and to look at the possible anti-inflammatory effects of iron deficiency in an animal model of arthritis. The model we chose is adjuvant disease, which is a well used model for testing anti-arthritis drugs. It was first documented by Pearson in 1956⁵ and has the advantage of being a well documented and reproducible model to use in the laboratory. The pathology of the joint differs from that of rheumatoid arthritis although one factor which is consistent is the presence of iron deposition within the synovium.

The protocol we used to produce our iron deficient rats was to feed male post weaning rats with an iron deficient diet containing 20 parts per million of iron. Control rats were fed the same diet, supplemented with ferrous sulphate. Using this level of iron deficiency in the test group there was no significant difference in weight gain compared with controls on the supplemented diet and hemoglobin levels were only mildly reduced, although iron stores were significantly reduced. Interestingly the levels of other metals such as copper were not affected by the level of iron deficiency in this experiment.

Having produced iron deficiency we then went on to induce adjuvant disease. This was done by injecting mycobacterium butyricum intradermally into the tail. Twelve days later rats developed the characteristic components of adjuvant disease; firstly local inflammation at the site of the injection and then joint symptoms and a systemic response to the adjuvant. I will just concentrate on the joint symptoms. Suffice to say that iron deficiency had no effect on local or systemic responses.

Iron deficiency did have profound effect on the joint symptoms. Figure 1 (page126) shows a typical arthritic ankle joint from a normal rat with normal iron levels, 28 days post adjuvant injection showing extensive inflammation. Figure 2 (page126) however shows a typical iron deficient rat ankle joint also 28 days post adjuvant injection where one can see only a very mild inflammation. We assessed joint inflammation in three ways. Firstly by visually scoring redness and swelling from 0-4 for each hind ankle joint, with a maximum score of 8 per rat and the results can be seen in Figure 3 (page128). At the beginning of the experiment there was a high percentage of animals with a score of 0, as one would expect. As the arthritis progressed in the control group more animals had a higher score. However in the iron deficient group we demonstrated the anti inflammatory

effects of iron deficiency by the significantly higher numbers of rats that had a score of 0 from day 16 to the end of the experiment.

We also assessed joint inflammation by scoring typical histological features of arthritis; inflammatory cell infiltration, synovitis, fibrin deposition and bone erosion, new bone formation and repair of the joint tissue. Again these were scored from 0-4 on sections cut through the right ankle joint of each rat. We obtained similar results to the gross scoring with a significant reduction in histology score in the iron deficient rats towards the end of the experiment (Figure 4). Figure 5 (page115) shows a typical haematoxylin and eosin stained section cut through the hind ankle joint of a control rat 28 days post adjuvant. The joint is almost totally destroyed. The joint space and a large proportion of the bone has been replaced by inflammatory cell infiltration. Thus bone has been eroded away and eventually the joint will collapse.

Figure 6 (page115) shows a typical iron deficient rat joint section at the same time point with very little inflammation. All the iron deficient rats did show some histological signs of inflammation, but at the most it was a mild synovitis.

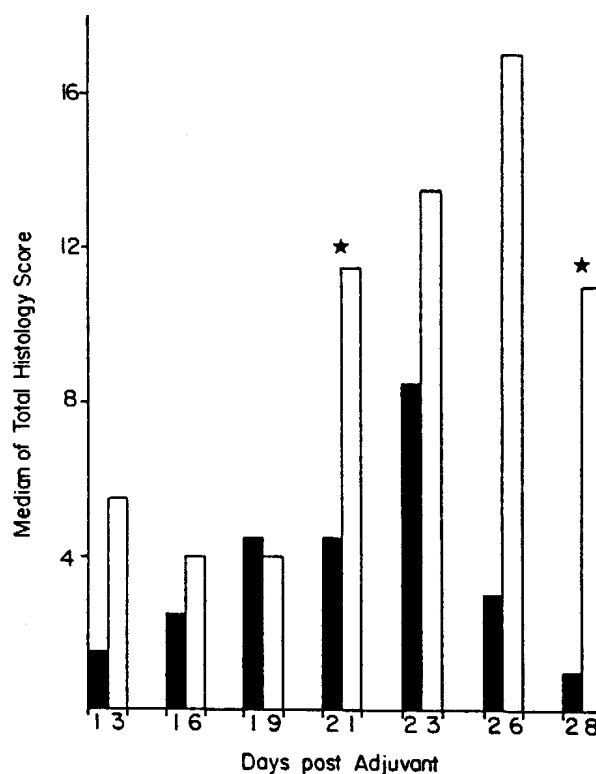


FIGURE 4. A comparison of the medial total histology scores during the course of adjuvant disease in iron deficient and iron supplemented rats. Solid columns = iron deficient, hollow columns = iron supplemented. * p < 0.05 (Mann Whitney Test)

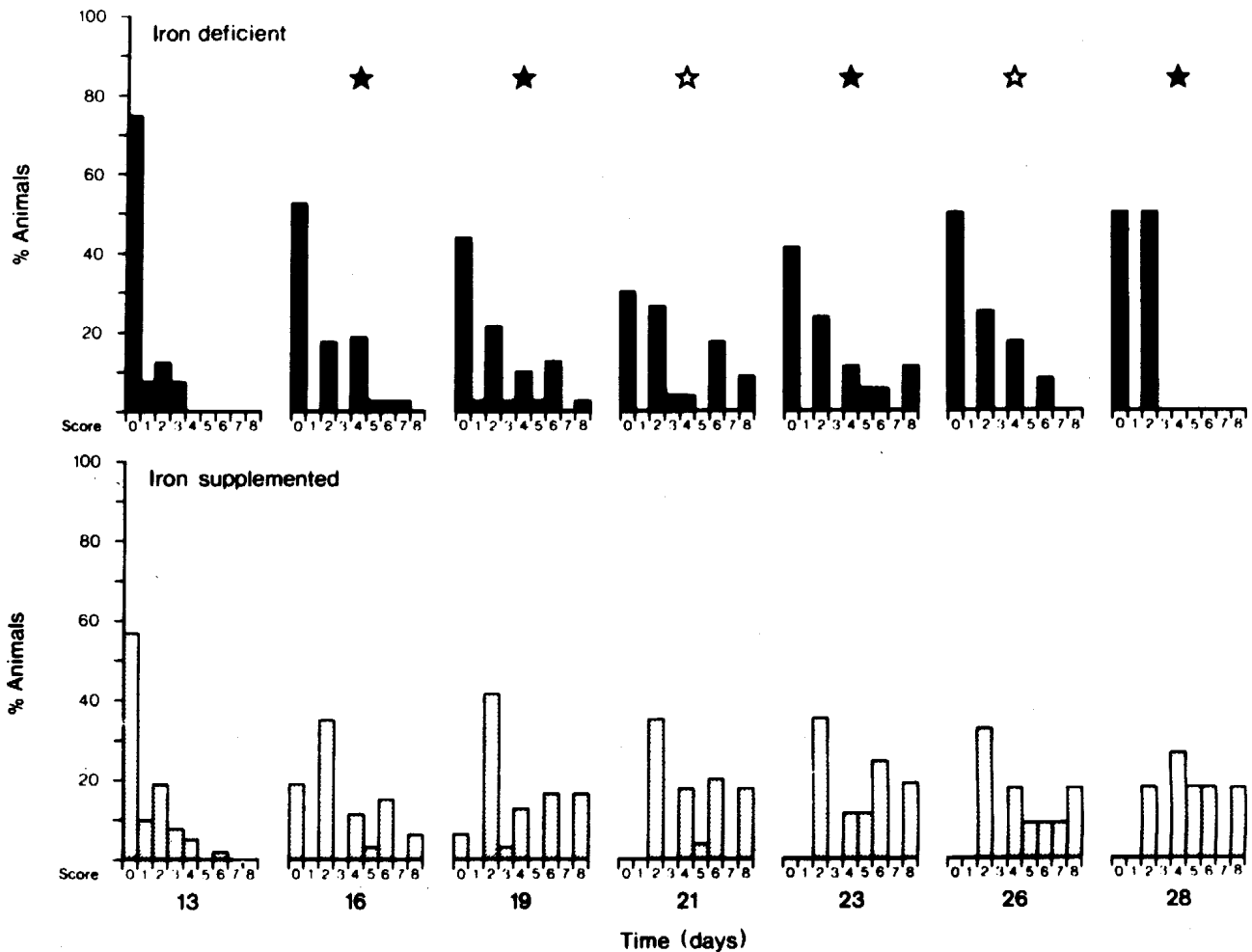


FIGURE 3. A comparison for the visual scores of redness and swelling, from 0-4 for each hind ankle joint with a maximum score of 8 per rat, at various times after injection of adjuvant in iron deficient and iron supplemented rats with adjuvant disease. *(solid) = $p < 0.05$ *(hollow) = $p < 0.01$ (Mann Whitney Test)

The third method by which we assessed inflammation in the joints was by scoring the following radiological features; bone density, new bone formation and soft tissue swelling, again from 0-4. This time we used the left ankle joint from each rat so that we had a comparison with the histological sections taken from the right joint. Results of scoring showed a similar picture to the histology with a reduction in radiological features of adjuvant disease in the iron deficient rats towards the end of the experiment (Figure 7).

Figure 8 (page 130) shows a typical radiograph of a control rat, 28 days post adjuvant showing a decrease in bone density, new bone formation and extensive soft tissue swelling. Figure 9 (page 130) however, shows a typical iron deficient rat joint at the same time point with no bone changes. So in summary we found that iron deficiency had no effects on local and systemic responses to adjuvant but did significantly reduce the joint inflammation as assessed by histology radiography and visual scoring.

As there is some evidence that reactive oxygen metabolites are involved in joint inflammation in rheumatoid disease, we went on to see if they played any role in this adjuvant model. We were proposing that iron deficiency might reduce the production of reactive oxygen metabolites in the joint tissue by preventing the formation of the toxic hydroxyl radical. It is very difficult to measure reactive oxygen metabolites directly because of their reactivity. However, it is possible to detect reactive oxygen metabolite activity using the chemical Luminol which reacts with oxidising species, such as the hydroxyl radical, producing an electronically excited ion which on returning to the ground state emits a photon. This process is known as chemiluminescence.

To investigate chemiluminescence as an indicator of reactive oxygen metabolite reactivity in the joint tissue, we induced adjuvant disease systemically as before, but this time we challenged the rats with a second injection of Freund's adjuvant into the foot pad. This gives an immediate

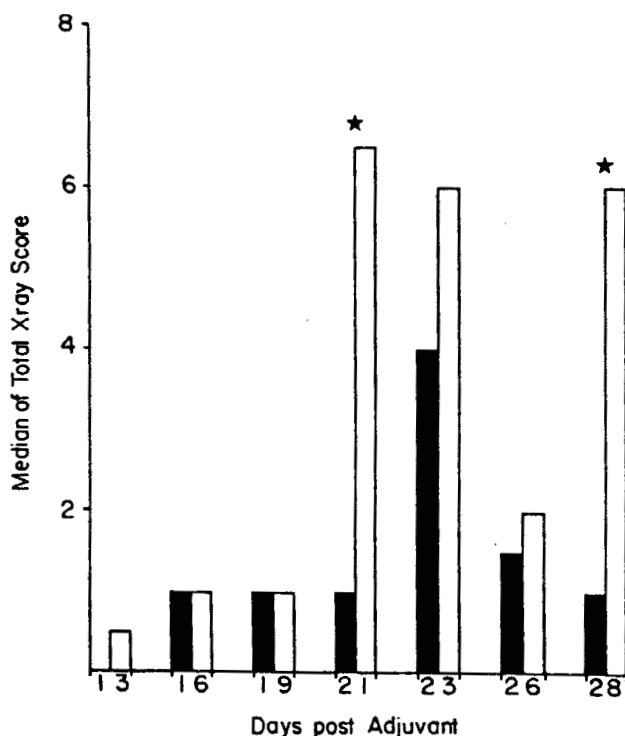


FIGURE 7. A comparison of the median total X-ray scores during the course of adjuvant disease in iron deficient and iron supplemented rats. Solid columns = iron deficient, hollow columns = iron supplemented. * $p < 0.05$ (Mann Whitney Test).

inflammatory reaction. We removed the inflamed tissues at various times and immediately placed them into Luminol. Luminol amplified chemiluminescence was then measured using a Wallac 1216 scintillation counter set in the out of coincidence mode.

Initially reactive oxygen metabolite activity as measured by chemiluminescence was quite low in both sets of animals but then at 6 hours there was a sudden increase in reactive oxygen metabolite activity in the control animals and this was suppressed by the iron deficiency (Figure 10).

Inflammation in these animals was assessed by removing and weighing the inflamed tissues. Again a similar result was found, from 6 hours onwards the inflammation was reduced in the iron deficient animals (Figure 11, page 131). So there was a reduction in inflammation which coincided with a reduction in the sudden boost in reactive oxygen metabolite activity in the tissues.

In conclusion, iron deficiency appears to specifically protect the joint in rats with adjuvant disease. The anti-inflammatory effects of iron deficiency may be due to reduction in oxidative tissue damage. To return to the rheumatoid patients we suggest that after the initial inflammatory insult, iron deposition derived from microbleeding, sequestered within the synovium promotes further inflammation via oxidative mechanisms.

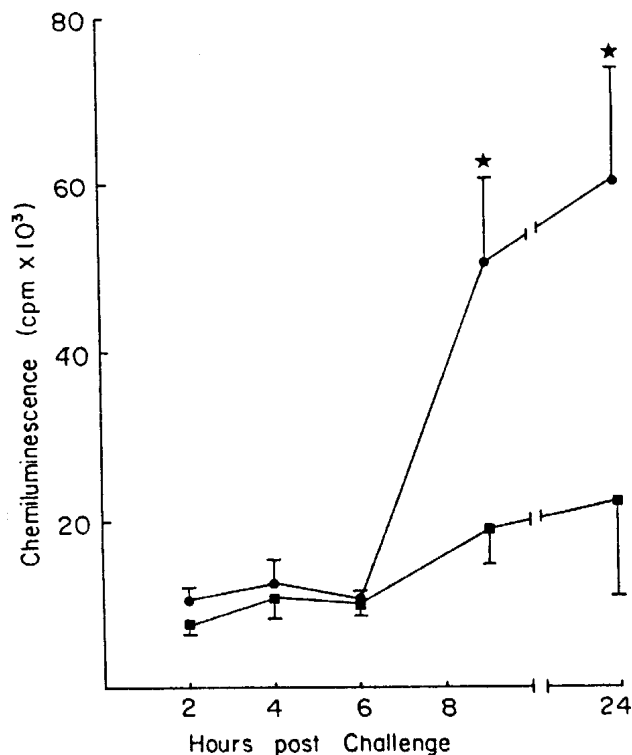


FIGURE 10. A comparison of the production of Luminol amplified chemiluminescence from the inflamed foot pad tissue of iron deficient and iron supplemented rats after challenge with Freund's complete adjuvant. Solid squares = iron deficient, solid circles = iron supplemented. * $p < 0.05$ (Student's Test).

Edited comments from the question and answer session appear below

Dr Janet Vial

What is the relationship with iron and copper, because certainly copper compounds seem to give relief to arthritis?

Dr Fiona Andrews

In our study we found that copper levels were unaffected by the iron deficiency and were in the normal range for rats thus it would be difficult to speculate on the specific effects of copper on the arthritic process in this model from this work.

Dr Janet Vial

Copper is involved with superoxide dismutase which is one of the protective mechanisms against free radicals. Certain copper complexes can actually act in the same way as superoxide dismutase. There is a bit of experimental evidence that if one combines non steroidal with copper one can enhance their anti inflammatory activity and pain relieving ability quite significantly. This is still laboratory based work so maybe it is not quite so much an old wives tale as

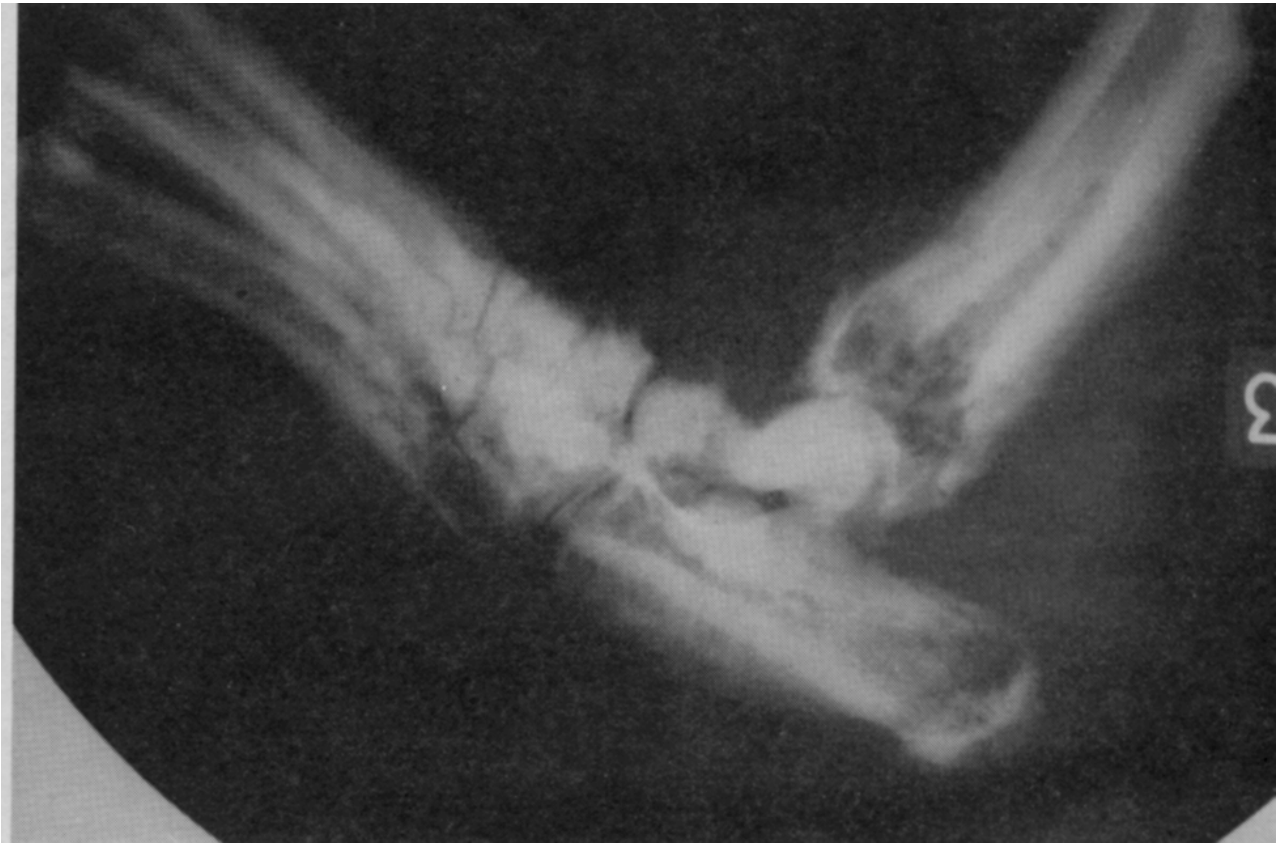

FIGURE 8. A typical radiograph of a control rat, 28 days after adjuvant injection showing a decrease in bone density, new bone formation and extensive soft tissue swelling.

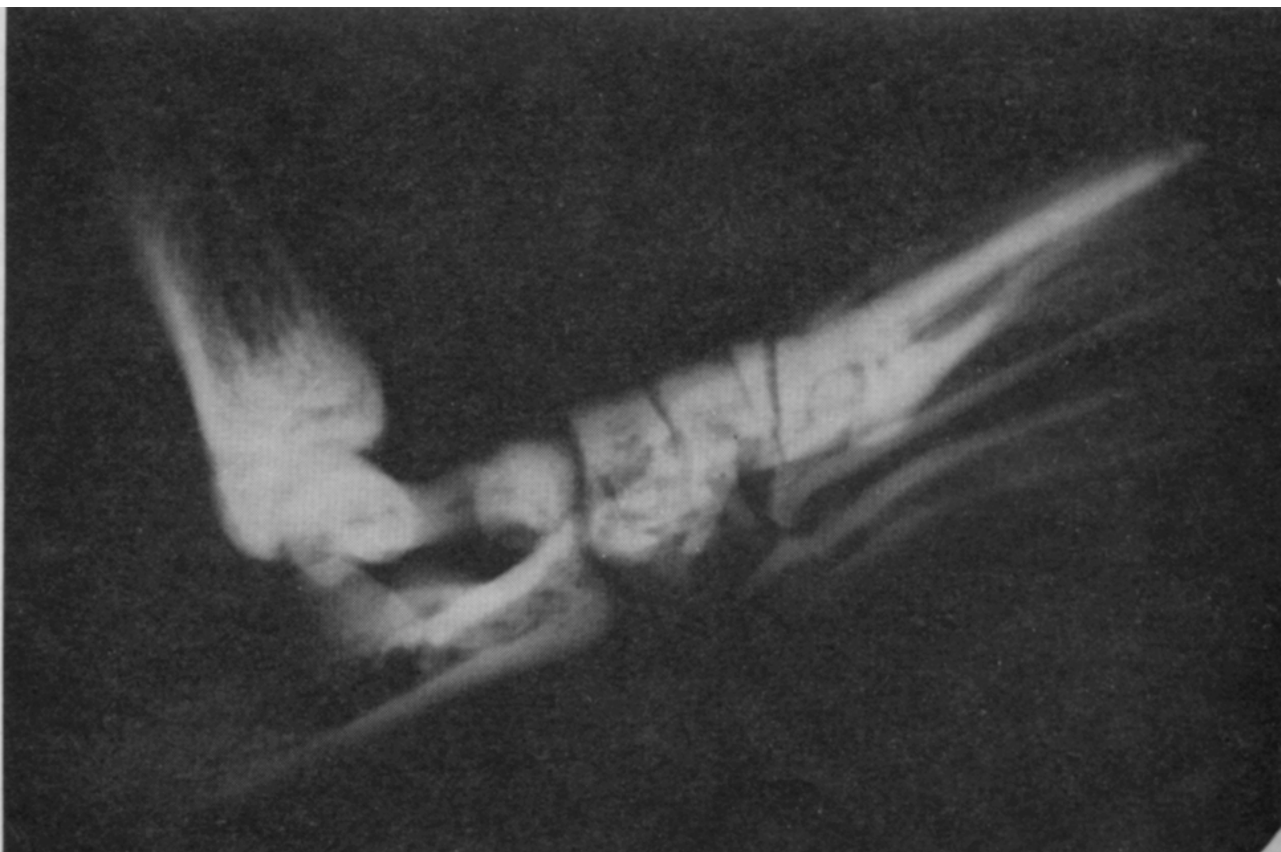

FIGURE 9. A typical iron deficient rat joint 28 days after adjuvant injection with no bone changes.

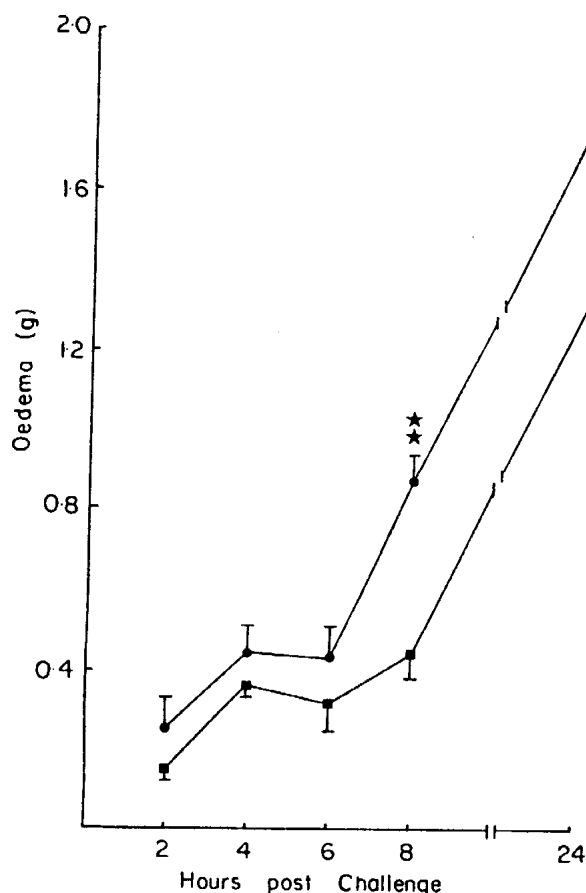


FIGURE 11. A comparison of the development of foot pad oedema in iron deficient and iron supplemented rats after challenge with Freund's complete adjuvant. Solid squares = iron deficient, solid circles = iron supplemented. * $p < 0.05$, ** $p < 0.01$ (Student's Test).

perhaps people have thought. Maybe in the future we will be seeing copper complex non steroidal agents.

Mr Christian Narkowicz

Is there any way of binding free the iron in the joints?

Dr Fiona Andrews

There has been some work to suggest that infusion of desferrioxamine into a model of inflamed synovial-like tissue, namely the allergic air pouch in rats, reduces the inflammatory reaction although I am not aware of studies where desferrioxamine has been infused into the human arthritic joint.

REFERENCES

- 1 Muirden KD. Ferritin in synovial cells in patients with rheumatoid arthritis. *Ann Rheum Dis* 1966; 25: 387-401.
- 2 Muirden KD. The anaemia of rheumatoid arthritis: The significance of iron deposits in the synovial

membrane. *Aust Ann Med* 1970; 2: 97-104.

- 3 Lunec J, Halloran SP, White AG and Dormandy TL. Free radical oxidation (peroxidation) products in serum and synovial fluid in rheumatoid arthritis. *J Rheumatol* 1981; 8: 233-245.
- 4 Winyard PG, Blake DR, Chiricos, Gutteridge JMC and Lunec J. Mechanism of exacerbation of rheumatoid synovitis by total dose infusion of iron dextran: In vivo demonstration of iron promoted oxidant stress. *Lancet* 1987; 1: 69-72.
- 5 Pearson CM. Development of arthritis, peri-arthritis and periostitis in rats given adjuvants. *Proc Soc Exp Biol Med* 1956; 91: 95-101.

This is an edited transcript of a recording made at a Free Radical Workshop during the joint SPUMS and Royal Hobart Hospital meeting on Hyperbaric and Diving Medicine in November 1988.

Dr Fiona Andrews' address is Department of Surgery, Monash University Medical School, Alfred Hospital, Commercial Road, Prahran, Victoria 3181, Australia

FREE RADICALS IN HEALTH AND DISEASE

Janet Vial

An alternative title for my talk today would be oxygen, friend or foe. I am sure Joseph Priestly in 1775 never really appreciated the implications of his words when he wrote, "Though pure dephlogisticated air (which was his name for oxygen) might be useful as a medicine it might be not so proper for us in the usual healthy state of the body for as the candle burns so much faster in dephlogisticated than in common air so we might as may be said live out too fast and the animals powers be too soon exhausted in this pure kind of air". So from the very beginning Priestly perhaps appreciated the mixed blessing that oxygen is. Although we can point to many substances in our environment which are both good and bad, perhaps oxygen is unique in being essential to life but also being so potentially toxic to living cells.

I would like to go back in time. Back five billion years to the beginning of the earth. When the earth was