

The outcome of 125 divers with dysbaric illness treated by recompression at HMNZS PHILOMEL. *SPUMS J* 1990; 20: 226-230

- 11 Moon RE, Gorman DF. Treatment of the decompression disorders. In: Bennett PB and Elliott DH. Eds. *The physiology and medicine of diving (4th ed)*. London: WB Saunders Ltd, 1993: 506-541

Marysha Gardiner is a sixth year medical student who completed an elective in diving and hyperbaric medicine at the Royal New Zealand Navy Hospital from October to December 1995.

Christine Forbes, RN, is the senior hyperbaric nurse at the Slark Hyperbaric Unit, Royal New Zealand Navy Hospital.

Dr Simon Mitchell, MB ChB, DipDHM, is a full time Medical Officer at the Slark Hyperbaric Unit, Royal New Zealand Navy Hospital.

Address for correspondence, Dr Simon Mitchell, Slark Hyperbaric Unit, Royal New Zealand Navy Hospital, Naval Base, Devonport, Auckland, New Zealand.

AN UNUSUAL CASE OF CEREBRAL ARTERIAL GAS EMBOLISM

Christopher Butler, David King and David McManus

Abstract

A snorkel diver suffered a cerebral arterial gas embolism after breathing, at depth, from the octopus regulator of a scuba diver. The neurological injury was manifested by loss of consciousness and by cortical blindness. The chest X-ray demonstrated multiple signs of pulmonary barotrauma. An MRI scan demonstrated cerebellar infarction. The unusual aspects of this case and the pathophysiology of pulmonary barotrauma are discussed.

Key Words

Accident, air embolism, barotrauma, cerebral arterial gas embolism, eyes, pulmonary barotrauma, treatment, unconscious.

Introduction

Pulmonary barotrauma and cerebral arterial gas embolism (CAGE) are usually associated with scuba

diving accidents. We describe CAGE in a snorkel diver demonstrating a number of unusual features.

Case Report

A previously fit 23 year old male was snorkel diving on the Great Barrier Reef. His snorkel diving experience is unknown. He had never dived with scuba. He dived to a depth of 3-5 m and took several breaths from the octopus regulator of an accompanying scuba diver. Then he made an uncontrolled ascent to the surface.

On reaching the surface he was unconscious and had to be rescued. In the boat he was seen to be pale, tachycardic and tachypnoeic. CAGE was immediately suspected, so he was placed supine. Oxygen was given at a flow rate of 15 l/min using a non-rebreathing mask. After 45 minutes the flow was reduced to 10 l/min. He rapidly recovered consciousness, but appeared to be almost completely blind. No formal assessment of vision was carried out on the boat and the patient had no subjective improvement in his vision before recompression. He had no other symptoms or signs.

Urgent helicopter transfer to the local base hospital was arranged. Examination in hospital, an hour and 50 minutes after surfacing and 30 minutes after leaving the boat by helicopter, demonstrated he had difficulty in recognising shapes but normal visual fields to confrontation. This was unusual as occipital blindness usually, but not always, shows loss of field before loss of acuity. Ocular movements were normal, with both pupils small and reacting directly and consensually to light. Fundoscopic examination showed injected fundi but normal discs and no visible haemorrhages. A chest X-ray demonstrated mediastinal emphysema, subcutaneous emphysema and bilateral pneumothoraces (Fig 1).

These findings were confirmed following transfer to Townsville General Hospital 6 hours after surfacing. An ophthalmological opinion was obtained and the visual changes were considered to be the result of bilateral central retinal artery (CRA) occlusions.

He was initially managed with IV saline, IV lignocaine, a Comex 30 heliox table and bilateral digital ocular massage. He was compressed 6.5 hours after surfacing. His vision had improved considerably 85 minutes into the table, but deteriorated on ascent to 12 m.

He was taken back to 30 m and the table recommenced. After this extra time at depth improvement was sustained on ascent. After his first treatment his vision was 6/9 in both eyes.

The fundi were noted to be normal the following day. He had 3 further hyperbaric oxygen treatments (18 m for

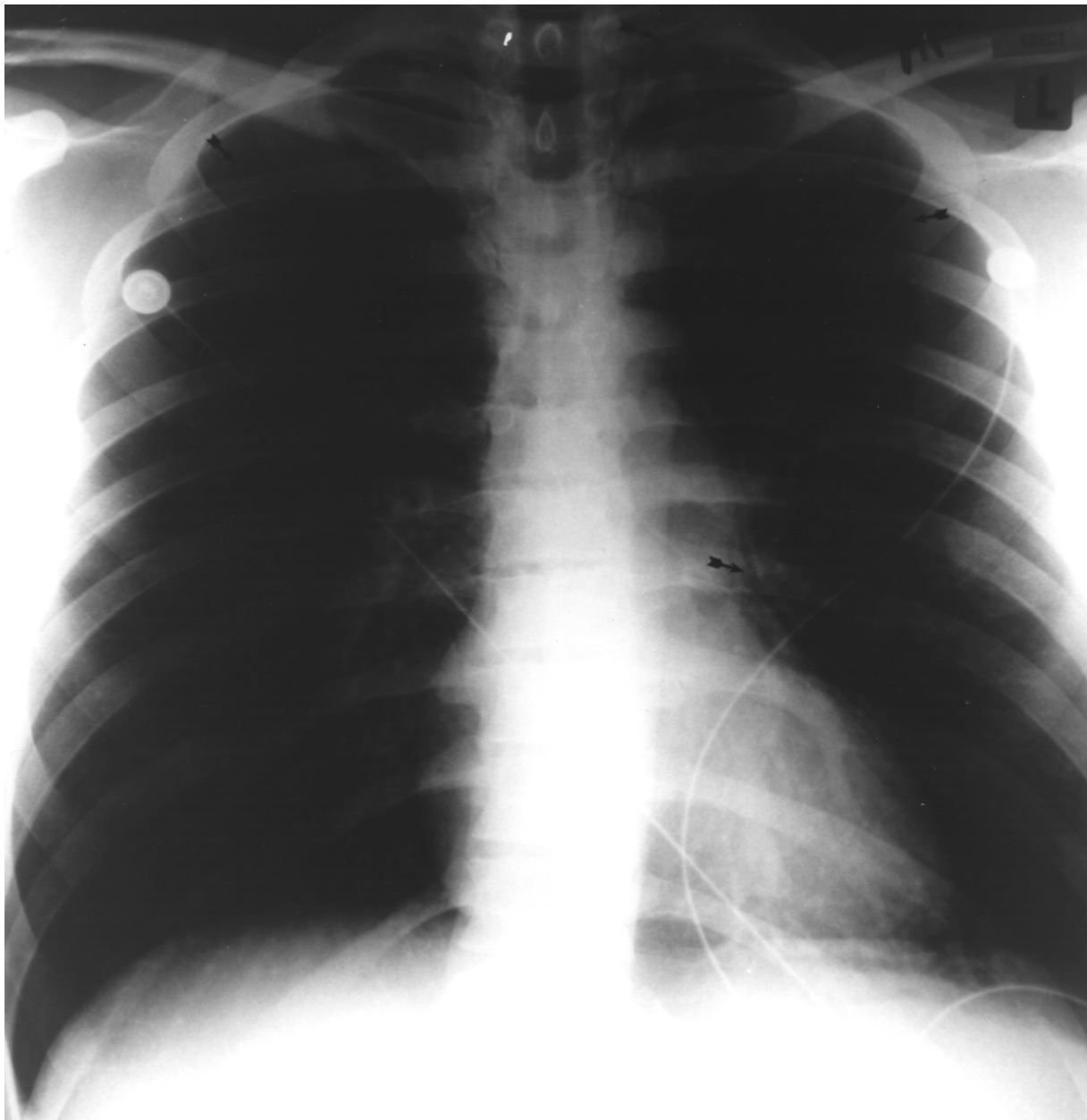

Figure 1. A-P chest X-ray demonstrating bilateral pneumothoraces, (black arrows at the level of left and right second ribs), left mediastinal emphysema (black arrow) and subcutaneous emphysema in the neck (white arrow).

60 minutes with a 30 minute ascent) in the next three days. He was discharged with bilateral 6/5 vision.

A T2 weighted magnetic resonance imaging (MRI) scan was performed 5 days after the accident (Fig 2). T2 is defined as the time constant that describes the exponential decay of the transverse magnetism of a tissue following a radio-frequency pulse (as opposed to T1, which describes the decay of longitudinal magnetism which is

faster). In practical terms, T2 scans differentiate an increased water content (oedema) of a tissue well. The scan demonstrated multiple signal abnormalities in the left cerebellar hemisphere. Small abnormalities were also noted within the subcortical white matter of the left frontal lobe. The appearance of these changes was consistent with areas of infarction, but did not correlate with any clinically evident neurological defect.

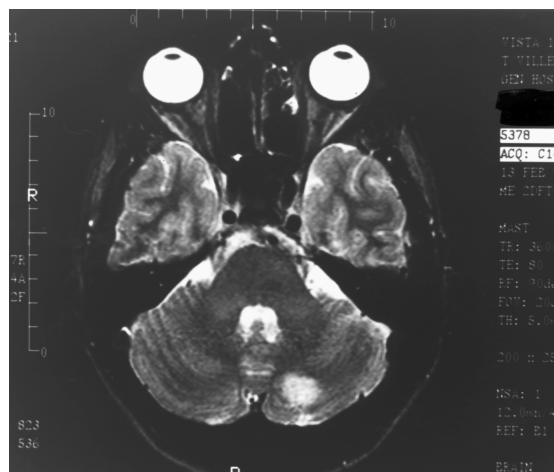


Figure 2. T2 weighted MRI scan of the head showing an area of infarction in the left cerebellar hemisphere.

Discussion

Pulmonary barotrauma, with or without associated CAGE is an important cause of diving fatalities, but the actual incidence is difficult to determine.¹

It has traditionally been accepted that the combination of pneumothorax and CAGE is uncommon, with an incidence of pneumothorax in divers presenting with CAGE of 5% or less.^{2,3} A more recent study demonstrated a higher incidence of other chest X-ray changes indicating pulmonary barotrauma associated with CAGE, but noted that the association with pneumothorax was still uncommon.⁴ These studies would indicate that cases demonstrating all the manifestations of pulmonary barotrauma (bilateral pneumothorax, mediastinal and subcutaneous emphysema and CAGE) are rare.

Lung overexpansion and pulmonary barotrauma producing CAGE in divers requires the breathing of compressed gas at depth. Subsequent ascent results in a fall in the ambient pressure and an increased lung volume. Such lung overexpansion is not associated with breath-hold diving from the surface, of which snorkel diving is an example. Two points can be made from this.

- 1 Snorkel divers when diving with scuba divers are potentially at risk of CAGE if they breathe compressed gas at depth. If a snorkel diver loses consciousness on surfacing, the first aid measures should bear this in mind.
- 2 Air breathed at a depth of 3 m is sufficient to produce lung rupture on ascent if the diver leaves the bottom with full lungs and does not exhale on the way

up. Lung rupture can potentially occur from a depth of 1 m.⁵

The pathophysiology of this patient's blindness was initially confusing. Formal perimetry and fundoscopy, through pharmacologically dilated pupils, were omitted to facilitate early recompression. The only clinical signs of CAGE were loss of consciousness and blindness. The initial diagnosis of bilateral CRA occlusions must postulate that the same terminal branches of two separate carotid circulations were selectively embolised, which is unlikely. The retina is very sensitive to hypoxia as it has minimal collateral circulation. Normal pupillary light reflexes, and a complete return of vision, are not consistent with prolonged total bilateral CRA occlusion. These features make the initial diagnosis of bilateral CRA occlusions very unlikely.

Cortical blindness has previously been described in divers presenting following arterial gas embolism.⁶ However it is interesting to note that this most severe clinical abnormality did not correlate with any change in the occipital cortex on MRI scan in this patient. The visual loss was not total, with selective aspects of function being maintained and a full recovery following treatment. This suggests localised and incomplete ischaemia of the distal posterior cerebral artery branches, which are supplied from the vertebro-basilar circulation.

Bubble effects arising from this system are confirmed by infarction of the cerebellum demonstrated on MRI. The loss of consciousness is consistent with transient brain stem ischaemia, which is also supplied by the vertebro-basilar system.

References

- 1 Edmonds C, Lowry C and Pennefather J. *Diving and Subaquatic Medicine. 3rd edition.* Oxford: Butterworth-Heinemann, 1992: 82-85
- 2 Pearson RR. Diagnosis and treatment of gas embolism. In *Physicians guide to Diving Medicine.* Shilling C, Carlston C and Mathias R. Eds. New York: Plenum Press, 1984: 336
- 3 Leitch DR and Green RD. Pulmonary barotrauma in divers and the treatment of cerebral arterial gas embolism. *Aviat Space Environ Med* 1986; 57: 931-938
- 4 Harker CP, Neuman TS, Olsen LK, et al. The Roentgenographic findings associated with air embolism in sport scuba divers. *J Emerg Med* 1993; 11(4): 443-449
- 5 Schaefer CP, McNulty WP, Carey C, and Lubow AA. Mechanisms in the development of interstitial emphysema and air embolism on decompression from depth. *J Appl Physiol* 1958; 13: 15-29
- 6 Greer HD. Neurological consequences of diving. In *Diving Medicine. 2nd edition.* Bove AA and Davis

JC. Eds. Philadelphia: WB Saunders, 1990: 224-225

Dr Christopher S Butler FANZCA, Dip DHM, is a Staff Specialist, Department of Anaesthesia and Intensive Care, Townsville General Hospital, Eyre Street, Townsville, Queensland 4810, Australia.

Mr David A King is a Hyperbaric Technical Officer at the Townsville General Hospital.

Dr David McManus, MB, BS, is Senior Medical Officer, Department of Emergency Medicine, Townsville General Hospital.

This case was presented at the Hyperbaric Technicians and Nurses Association (HTNA) Meeting in Hobart in August 1996.

RECOMPRESSION FACILITIES IN PALAU AND CHUUK

Timujin A W Wong

Abstract

During the Second Micronesian Anaesthetic Refresher Course, in October 1995, sessions were devoted to diving and hyperbaric medicine and the pathophysiology and treatment of decompression illness. After the course the hyperbaric facilities of the Belau National Hospital and Chuuk State Hospital were inspected. The January 1993 to October 1995 statistics for the Hyperbaric Unit in Palau were reviewed and the incidence of decompression illness in both regions is discussed.

Key Words

Decompression illness, hyperbaric facilities, teaching, treatment.

Introduction

In October 1995 the Second Micronesian Anaesthetic Refresher Course was held at the Belau National Hospital, Koror, Republic of Palau. Two anaesthetists from the Royal Hobart Hospital, Dr Malcolm Anderson and myself, were the guest lecturers. We were financially assisted by the Australian Society of Anaesthetists (ASA) and the World Federation of Societies of Anaesthesiologists (WFSA). During the organisation of the course, donations of medical

products and sponsorship were obtained from: Abbott Australasia Pty. Ltd., Anaesthetic Supplies Australia, Ansell International, Astra Australia, Mallinckrodt Medical, Ohmeda, Organon Teknika, Pacific Medical Supplies Pty. Ltd., Portex, Roche Products Pty. Ltd. and Statemed Pty. Ltd. These companies donated much needed medical supplies to the four regions of Micronesia. QANTAS, Continental Micronesia Airlines and Allways Dive Expeditions Travel Service kindly provided substantial discounts and luggage waivers to enable transport of the medical supplies to, and throughout, Micronesia.

The four day course consisted of lectures in the mornings followed by a series of case presentations and clinical scenarios in the afternoon. The meeting was attended by 14 medical and nursing personnel from the islands of Palau, Yap, Chuuk and Kosrae. The course was structured to cover the essential aspects of anaesthetic care in the areas of trauma, preoperative assessment, anaesthetic emergencies, obstetrics, paediatrics and regional anaesthesia. Also included in the course were sessions devoted to diving and hyperbaric medicine and the pathophysiology and treatment of decompression illness (DCI). These were well-attended by medical and nursing staff and also by a 65 year-old American tourist who had developed mild decompression symptoms before undergoing his first treatment in Palau's new recompression chamber. On one evening, the Palau Pacific Resort provided facilities to deliver a lecture on diving emergencies to local medical staff and diving organisations.

After the course, I stayed in Palau for an additional five days and then a week in Chuuk to participate in further practical teaching in anaesthesia and to review the hyperbaric facilities of the Belau National Hospital and the Chuuk State Hospital.

The Belau National Hospital

The Belau National Hospital is a new establishment, about four years old, and has 120 beds serving a population of approximately 40,000. The medical facilities in Palau were very impressive for such a small island as the hospital was modern and well-equipped. This was in contrast to the very basic conditions found in other Micronesian islands such as Chuuk, Yap and Kosrae. The Belau National Hospital's most impressive acquisition is the new hyperbaric facility. In June 1995, a new multiplace recompression chamber was installed with the help of the US Navy, the National Ocean and Atmospheric Administration (NOAA), the Republic of Palau, the Koror Chamber of Commerce, the Professional Association of Diving Instructors (PADI), the National Association of Underwater Instructors (NAUI), the Divers Alert Network (DAN) and numerous other local and American supporters. The new multiplace recompression chamber replaced an outdated monoplace unit.