

# Dangerous Australian box jellyfish

Peter J Fenner

## Key words

Marine animals, jellyfish, envenomation, review article

## Abstract

(Fenner PJ. Dangerous Australian box jellyfish. *SPUMS J.* 2005; 35: 76-83.)

Each year in the tropical waters of Australia, just south of the Tropic of Capricorn on the east coast and extending northwards and then westwards to Exmouth in Western Australia, serious envenomation can occur from two major species of box jellyfish. *Chironex fleckeri*, a multi-tentacled box jellyfish (chirodripid) has caused 68 fatal stings since 1883. Injuries vary from life-threatening stings affecting the conscious state, the breathing or the circulation of the victim, to smaller stings that cause severe local skin pain. *Carukia barnesi*, commonly known as the 'Irukandji', is a single-tentacled box jellyfish (carybdeid) causing stings that produce severe, rarely life-threatening systemic symptoms. The number of stings from this species varies considerably from year to year from a few to several hundred. However, in some years potentially life-threatening stings present, suggesting there may be two main 'groups' of Irukandji – the first, *Carukia barnesi*, causing the classical syndrome with its severe, unpleasant but non-life-threatening systemic symptoms; and the other, a different species or group, causing a severe syndrome responsible for two human fatalities in 2003. This article describes the symptoms caused by each species and the first-aid and medical treatment of the stings.

## Introduction

Tropical Australian beaches and the adjacent waters including the Great Barrier Reef are amongst some of the best in the world for both scenery and opportunities for great recreational water activities, including reef diving and snorkelling for coral and fish viewing. However, in the hot summer months potentially lethal box jellyfish share these waters. These box jellyfish fall into two groups or genera:

- Chirodripids – box-shaped jellyfish with up to fifteen tentacles in each corner. The most common of these being *Chironex fleckeri*, which can cause immediate, severe, burning pain and depending on the extent of the sting may cause life-threatening respiratory or cardiac arrest within minutes.
- Carybdeids – box-shaped jellyfish with a single tentacle in each corner. There are many types of carybdeids throughout Australia, but in summer months it is the Irukandji group of jellyfish whose sting can cause severe systemic symptoms that completely prostrate their victim, and in some areas may cause life-threatening symptoms and even death. Species of Irukandji are present from coastal waters and deeper waters right out to and including the Great Barrier Reef.

### *Chironex fleckeri*

Although the first death from a jellyfish sting in Australia was in 1883, the causative jellyfish was not discovered until 1955. It was then that Hugo Flecker, a radiologist in Cairns (Figure 1), caught several large, box-shaped jellyfish in the waters near Tully, North Queensland, where a young child died after being stung. Southcott confirmed that this

jellyfish was a new species and genus and in 1956 named it *Chironex fleckeri* (Figure 2) after Flecker.<sup>1</sup>

There have been 68 deaths in Australia from *Chironex* since the first was described in 1883.<sup>1-4</sup> *Chironex* stings cause instant, severe skin pain, similar to being branded with burning irons. In large stings (more than 50% of the area of one limb) impaired consciousness, breathing and circulation may occur leading to death within three minutes.<sup>2</sup> The severity of sting depends on the area of envenomation (also depending on the width and the length of tentacles) and the intimacy of skin contact, which may be partially reduced due to the presence of hair. The latter may be a reason why relatively hairless victims such as children, who also have a greater surface-area-to-mass ratio, suffer more serious stings. Children account for 53 of the 68 deaths from *Chironex*.<sup>2</sup> In *Chironex* stings, tentacles avulsed from the animal by the struggling victim in the water adhere firmly to the skin, anchored by vast numbers of discharged nematocyst tubules buried in the victim's skin.

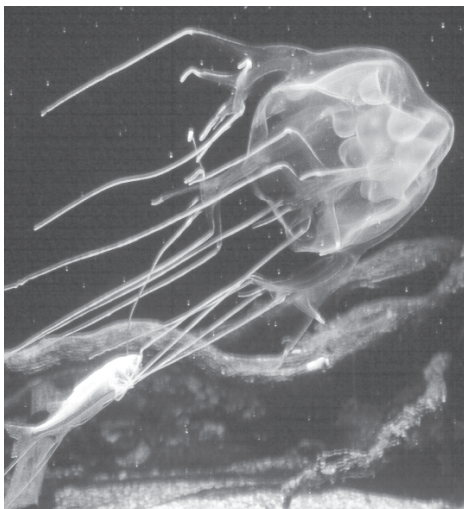
Tentacle contact causes severe, localised skin pain, with weal formation and blistering occurring within six hours (Figure 3). A 'ladder' pattern may be seen glistening in the sun on the stung area (Figure 4), caused by remaining discharged nematocysts on the skin surface.<sup>3</sup> This ladder pattern matches the arrangement of 'batteries' of nematocysts on the jellyfish tentacle (Figure 5). Usually, in the next 24 hours the skin becomes necrotic (Figure 3) and tends to scar for life (Figure 6).

Ice or cold packs alleviate minor skin pain but they are of less benefit after major envenomation because of deep skin

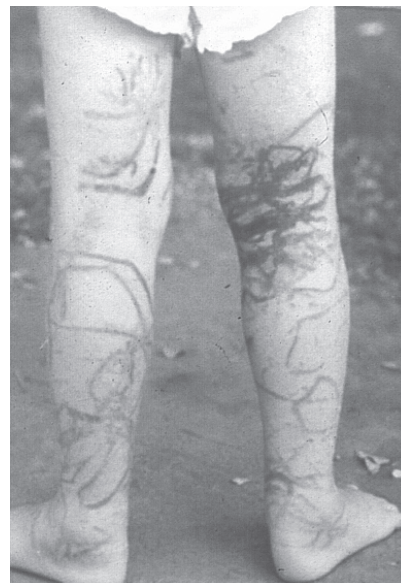**Figure 1**  
**Hugo Flecker**  
(courtesy John Pearn)



**Figure 2**  
*Chironex fleckeri*, the box jellyfish




**Figure 3**  
*Chironex* sting:  
typical skin pattern



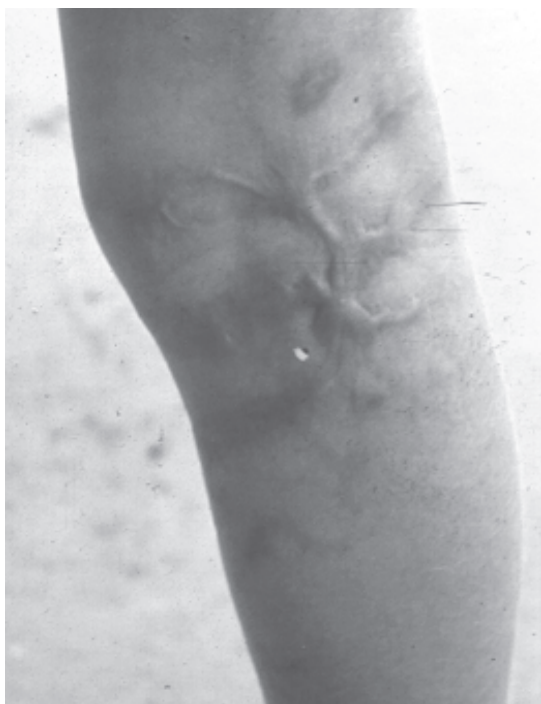
**Figure 4**  
*Chironex* sting : typical skin 'ladder' pattern



**Figure 5**  
The arrangement of 'batteries' of nematocysts on a  
*Chironex* tentacle



**Figure 6**  
Scarring of the skin after a serious *Chironex* sting

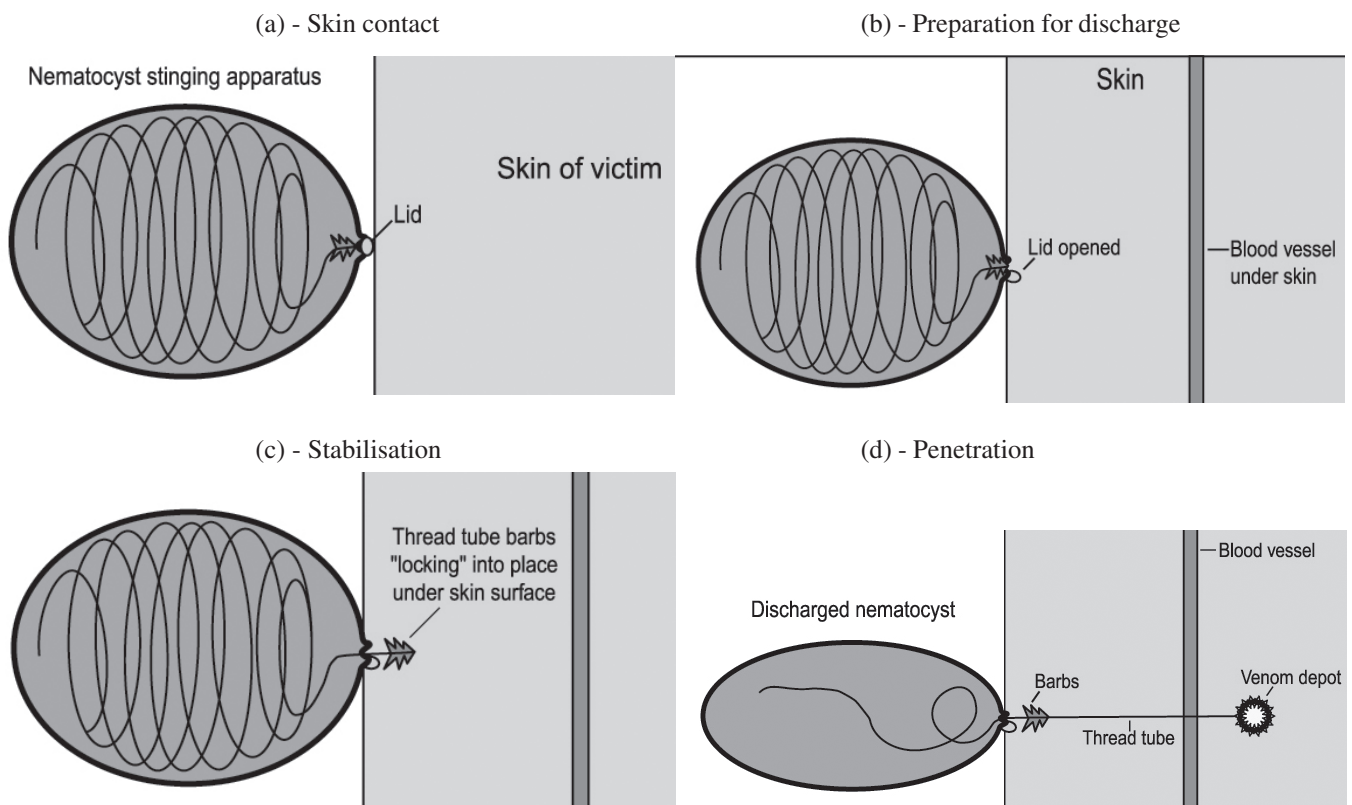


damage and severe pain. Although some victims are taken to hospital, only 1–2% are admitted (Fenner, unpublished data from sting database) with exact numbers of stings unknown and unobtainable.

*Chironex* envenomation is probably the most rapid envenomation process known, with unconsciousness, and respiratory or cardiac arrest occurring within minutes, often on the beach before appropriate first-aid treatments are commenced. The victim may be screaming with pain one moment but suddenly become quiet and 'co-operative' due to rapid unconsciousness where the need for resuscitation may be imminent.<sup>2-4</sup>

### Method of jellyfish envenomation

Injection of the venom occurs from a specialised cell called the nematocyst. Millions of nematocysts are present in the tentacles of a jellyfish. Each nematocyst has a thread tube that is tightly coiled inside a capsule. On the outside of this nematocyst is a 'lid' with a 'trigger'. When this trigger touches the integument of a potential victim, it is stimulated by both the taste (chemical) and touch (tactile) of the potential prey ((a) - Skin contact). This causes the lid of the nematocyst to open ((b) - Preparation for discharge). The thread tube then everts itself in just a few thousandths of a second, driving through the skin of its victim with tremendous force and speed. The first part of the discharging thread tube has a set of 'spines' that 'lock' into the epidermis ((c) - Stabilisation). The thread tube extends into the dermis and venom from the inside of the cell then passes down the tube and is deposited into the dermis ((d) - Penetration). As the thread everts, venom is present on the outside of the thread tube and when this tube punctures microscopic blood vessels, venom is introduced directly into the blood stream, accounting for the rapid onset of symptoms in massive *Chironex* box jellyfish envenomation.



#### FIRST AID FOR *CHIRONEX* ENVENOMATION

- Retrieve the victim from the water and restrain if necessary (activity causes an increased heart rate and faster absorption of venom from muscle contraction).
- Send others for an ambulance and/or medical help.
- Assess the conscious state and treat airway, breathing and circulation.
- Pour vinegar liberally over the stung area for at least 30 seconds to inactivate remaining stinging cells of adherent tentacles on the skin.
- Use oxygen, if available, for severe envenomation; Entonox (50% nitrous oxide, 50% oxygen) for severe pain. Entonox is contra-indicated in scuba divers who have recently been diving.
- In Queensland, the ambulance service has *Chironex* antivenom available. If the victim is unconscious, or if there is evidence of life-threatening cardiac or

respiratory decompensation, three ampoules are given intramuscularly by ambulance officers, or one ampoule intravenously by paramedics.<sup>5</sup>

#### Vinegar

Pour vinegar liberally over the area of the sting for at least 30 seconds to stop further nematocyst discharge. Do not rub the stung area either before or after the application of vinegar. After vinegar use, it is unnecessary to waste time removing the tentacles. However, if vinegar is not available for a major sting, pick off the bulk of the adherent tentacles as quickly and as gently as possible without compromising resuscitation. The skin of the rescuer's fingers is too thick to permit substantial penetration by nematocysts although a faint prickling sensation may be felt on the fingers during handling of tentacles that have not been treated with vinegar. Wash hands carefully to remove these nematocysts,

and subsequently apply vinegar for at least 30 seconds at the earliest opportunity. There is currently no effective substitute for vinegar in inactivating unfired chirodroid nematocysts. However, if vinegar is not available Coca Cola™ has been shown to be of limited benefit as an alternative.<sup>6</sup> Vinegar does NOT stop the skin pain.

#### MEDICAL MANAGEMENT FOR *CHIRONEX* ENVENOMATION

- If the victim is unconscious, or in life-threatening cardiac or respiratory decompensation, or demonstrating severe arrhythmias, antivenom can be given intravenously (the ampoule of 20,000 units is diluted 1:10). In a life-threatening situation three (or more) ampoules may be given intravenously and consecutively if the clinical response is inadequate.
- For persistent life-threatening cardiac decompensation or arrhythmia after antivenom use, consider giving verapamil intravenously ( $0.1 \text{ mg.kg}^{-1}$ , up to 5 mg adult dose) while continuing cardiopulmonary resuscitation.<sup>7</sup> Questions have been raised regarding the efficacy and safety of verapamil but in critical cases it should be considered.<sup>8,9</sup> Inotropic support may be required for persisting hypotension, but calcium is contra-indicated.
- Cardiopulmonary resuscitation, employing oxygen-enriched air (preferably 100% oxygen) should continue until after consideration of further therapy with more antivenom (at least six ampoules total dose if available) and consideration of more verapamil and inotropes. Intermittent positive pressure ventilation will assist in the control of pulmonary oedema.
- In non-life-threatening stings involving cosmetically sensitive areas (e.g., face or neck, especially in females), consider giving one ampoule of intravenous antivenom (administered as above) for potential cosmetic benefits.

#### Pressure bandaging

First aid using the pressure-immobilisation bandaging technique (PIB) has been advocated for major *Chironex* box jellyfish stings.<sup>2,4</sup> It was a technique originally developed to delay absorption of venom in snakebite.<sup>9</sup> However, it has now been shown *in vitro* that pressure can cause further discharge of nematocysts remaining on the skin, even after vinegar application, and PIB has been condemned by some groups, who have suggested that it will cause further envenomation of the victim.<sup>11</sup> However, this has never been shown in clinical use in major stings where PIB was used after initial treatment with vinegar.<sup>3,5</sup>

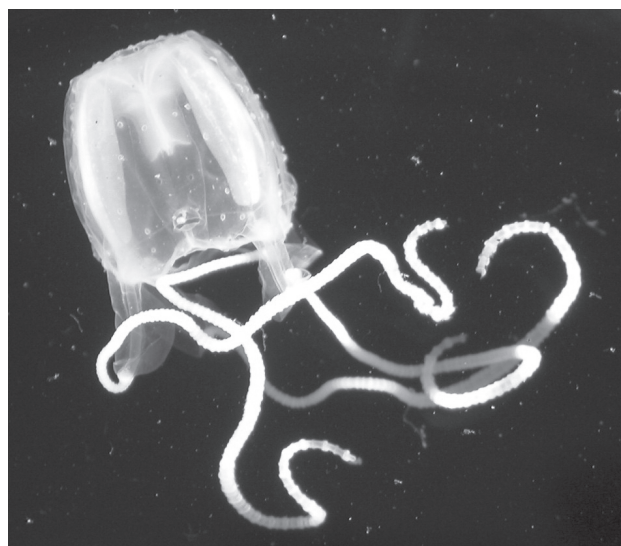The principle behind the use of PIB in major *Chironex* envenomation is that after resuscitation and vinegar application, this technique would 'buy time', as it does in snake envenomation. This enables rescuers to get the victim to hospital for intravenous access, antivenom and advanced resuscitation facilities. Although the Australian Resuscitation Council does not now recommend PIB,<sup>12</sup> the

outcome of its use awaits controlled evaluation and it could well be useful in certain cases.

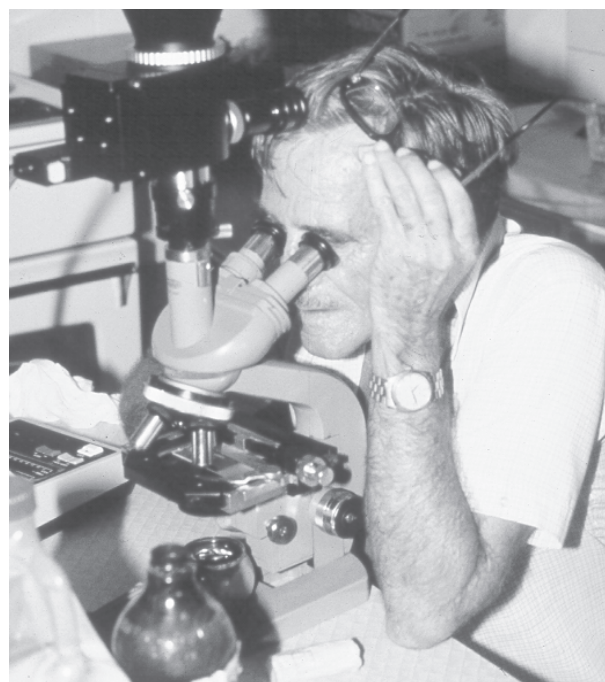
#### The Irukandji syndrome

In earlier days, the organism responsible for causing the delayed, severe systemic symptoms in swimmers in tropical waters in summer months in Australia was unknown. In 1952, Flecker named this set of severe systemic symptoms the 'Irukandji syndrome' after the Aboriginal tribe inhabiting the region around Palm Cove, north of Cairns, where many of the stings occurred.<sup>13</sup>

**Figure 7**  
*Carukia barnesi*, the 'original' Irukandji



**Figure 8**  
Jack Barnes



## THE IRUKANDJI (*Carukia barnesi*)

Jack Barnes caught two small carybdeids (box jellyfish) in shallow waters off Palm Cove in 1963 after some very careful detective work.<sup>14</sup> After stinging himself, his son and a friend, all of whom developed the full Irukandji syndrome, Barnes knew he had the true Irukandji. Southcott identified this jellyfish as an unknown species and genus and named it *Carukia barnesi* (Figure 7), after its intrepid discoverer (Figure 8).<sup>15</sup> It remains the only jellyfish to date proven to cause this syndrome in tropical Australian waters. *Carukia barnesi* has a transparent bell 10–12 mm in diameter, making it almost impossible to see in the water.<sup>16</sup> This small carybdeid jellyfish has one tentacle in each corner, each being 50–70 mm long when contracted, but extending to some 600–700 mm when the Irukandji is ‘trawling’ for its prey of small fish.<sup>2</sup>

## IRUKANDJI SPECIES

The slang (colloquial) name of Irukandji was previously used only for *Carukia barnesi*; however, recent research now suggests the syndrome is caused by at least 10 small carybdeids similar to the original *C. barnesi* and at least two larger carybdeid jellyfish (approximately 60–70 mm bell diameter at maturity; personal communication, Gershwin L-A, James Cook University, 2005). Consequently, the name Irukandji is now used loosely to describe any jellyfish causing the Irukandji syndrome.

## THE ‘CLASSICAL’ IRUKANDJI SYNDROME

Using original descriptions, the Irukandji syndrome can be defined as:

*The severe systemic symptoms developing some 30 minutes (20–40 minutes) after a sting from a small box jellyfish.*

The initial envenomation causes only minor skin pain with a faint red mark, which may be missed. Close inspection may reveal localised piloerection and sweating but these symptoms are usually totally missed. The initial envenomation is followed approximately half an hour later by a classical sequence of symptoms, including:

- Local pain
- Low back pain – severe boring pains in the sacral area.
- Muscle pain or ‘cramps’ in all limbs, the abdominal and chest-wall muscles. The pain is severe, unbearable and comes on in waves (similar to labour pains), never fading completely.
- Chest pain or tightness – spasm of the intercostal muscles (with no bronchospasm demonstrated); however, cardiac muscle pain and damage must be present, especially in more severe cases, as a rise in cardiac enzyme levels can be measured.

## Catecholamine excess

Many of the signs and symptoms associated with the Irukandji syndrome resemble those of an adrenal medullary tumour (phaeochromocytoma), or a funnel-web spider or scorpion envenomation, with excessive release of catecholamines into the bloodstream.

- Sweating – may be localised or generalised. It may be localised to the site of the sting, or a totally unrelated small area on the body. Often, it is generalised, profuse and drenching.
- Piloerection – localised or generalised, at the original site of envenomation, or an area totally unrelated.
- Anxiety and ‘wretchedness’ – the victim is over-anxious, feels absolutely dreadful and often describes a feeling of impending doom.
- Restlessness – the victim does not keep still, moves continuously, trying unsuccessfully to get comfortable.
- Headache – severe frontal, or global and incapacitating.
- Nausea – often with severe, intractable vomiting.
- Increased respiratory rate – rapid ‘sighing’ respiration.
- Tremor – a fine tremor, or fasciculation of the small muscles of the limbs.
- Pallor, or peripheral cyanosis – due to intense peripheral vasoconstriction.
- Oliguria – from both reduced renal perfusion and fluid loss from the sweating and/or vomiting.
- Tachycardia – fast and occasionally irregular, with ventricular extra-systoles.

Barnes was a meticulous record keeper and rarely, if ever, noted hypertension other than that associated with the pain of envenomation. He never described any life-threatening symptoms, although he was suspicious that a diving death in Townsville was connected to Irukandji envenomation.<sup>17</sup>

In 1998, a report of 60 Irukandji stings from Cairns also showed that the Irukandji syndrome, although unpleasant, had no life-threatening systemic effects.<sup>18</sup> The majority of patients were discharged after several hours’ monitoring in a specialised observation ward, without the need for admission.

## SEVERE IRUKANDJI SYNDROME

In the Whitsunday region and on the outer Great Barrier Reef (GBR) symptoms have been more severe than those in the Cairns area, with severe hypertension and pulmonary oedema being reported.<sup>19–21</sup> The 1998–99 season was also notable for the number of victims with severe toxic heart failure who needed admission to intensive care facilities for more complex treatment and investigations than usual. There have been other severe and unusual symptoms reported since, leading to the conclusion that there may be more than one species of jellyfish causing the Irukandji syndrome.<sup>22,23</sup>

### *Systemic symptoms in severe cases*

The skin pain seems to be sharper, and the severe and even bizarre systemic symptoms occur faster than in the classical syndrome, often starting some 5–20 minutes after the initial sting. The two recognised clinical sequelae of pain and catecholamine excess occur together with severe hypertension, which may reach levels as high as 300/180 mmHg in previously normotensive victims, and acute pulmonary oedema, which often develops some 15–18 hours post envenomation, occasionally less. Echocardiography shows marked global dilatation and left ventricular dysfunction, with a demonstrable rise in cardiac troponin levels, indicating an acute toxic myocarditis.<sup>21,22</sup>

Rarely, some people develop burning, neurasthenic pain in the lower limbs or in the jaw, priapism and acute angioedema within minutes of the initial sting and often this is accompanied by an audible wheeze.<sup>22</sup>

Skin scrapings to identify the species of Irukandji as 'classical' or 'severe' may be useful clinically.<sup>24</sup> However, it appears that the method described, using a scalpel blade, may cause marked scarring, and it may be better to revert to the suggested method by Currie et al of using sticky tape.<sup>25</sup>

### FATALITIES IN IRUKANDJI SYNDROME

Death from an Irukandji syndrome was first reported in 2002 in the Whitsunday Islands.<sup>26</sup> The victim quickly developed the severe Irukandji syndrome with marked hypertension within 15 minutes and, despite reaching medical aid, had an intra-cerebral haemorrhage, dying a few hours later from massive brain damage. A second death occurred in 2002 after an Irukandji jellyfish sting at the outer GBR, off Port Douglas. Again the victim suffered the severe syndrome with a blood pressure of 250/130 mmHg before having a major intra-cerebral bleed (personal communication, victim's partner).

The Irukandji syndrome has probably been responsible for other deaths in the past, mistakenly attributed to causes such as heart attack, cerebrovascular accidents, drowning or even diving deaths. Further severe, life-threatening Irukandji envenomation cases have been reported very recently from Western Australia.<sup>27</sup>

### DISTRIBUTION

The distribution of Irukandji stings has been confirmed to be from the Agnes Water area in Central Queensland, northwards around the north Australian coast, and then as far south as Broome in Western Australia. However, occasional cases of Irukandji syndrome have now been reported in Queensland as far south as Moore Park, Bundaberg. Although Irukandji stings often occur in deep water, including the offshore islands of North Queensland and the outer GBR, swarms may be brought to the surface at

coastal swimming beaches by underwater currents. Multiple stings may occur in summer months in these shallow waters.<sup>22</sup>

Irukandji sting numbers and intensities vary considerably each year. In some seasons there are 100–200 reported cases, whereas in others there may be very few. This may reflect variations in the ecology of species of jellyfish causing the Irukandji syndrome, and/or any unknown environmental, geophysical and geographical factors influencing their ecology.

### FIRST-AID TREATMENT FOR IRUKANDJI SYNDROME

There is currently no specific first-aid treatment for Irukandji stings. Recommendations are as follows.

- Remain with the victim, reassure them and encourage rest (muscle activity increases the heart rate and absorption and systemic dissipation of the venom).
- Douse the area with vinegar – although there are no visible, adherent tentacles, skin scrapings of the area show that, as with all jellyfish stings, there are remaining, unfired nematocysts. Vinegar prevents further discharge of nematocysts. It does not stop pain or inactivate the injected venom.
- Use sublingual nitrate spray, if available, to reduce the life-threatening hypertension in severe Irukandji syndrome.<sup>28</sup>
- Transport the victim to hospital by ambulance. The ambulance carries Entonox, a mixture of 50% oxygen and 50% nitrous oxide, which gives some pain relief, but further treatment in hospital is necessary. Entonox is contra-indicated if the stings occurred during scuba diving because of the risk of inducing decompression sickness with nitrous oxide.

### MEDICAL MANAGEMENT OF IRUKANDJI SYNDROME

There is no antivenom available, treatment being symptomatic.<sup>22</sup> Intravenous magnesium sulphate has proved to be very effective in the treatment of the signs and symptoms of Irukandji envenomation, greatly reducing pain and hypertension, and reducing all effects of the syndrome.<sup>29</sup> It is given either as boluses of 10 to 20 mmol magnesium sulphate, or as an infusion after an initial bolus of 30 mmol. It has few, if any, side effects in this dose. Respiratory support may be required until the severe symptoms are ameliorated.

### DIFFERENTIAL DIAGNOSIS

#### *Myocardial infarction*

Cases of Irukandji envenomation with chest pain, particularly if pulmonary oedema develops, have previously been misdiagnosed as acute myocardial infarction with developing heart failure.<sup>20</sup> This may be reinforced by a history of swimming (exertion), especially if the history of

a mild sting is not elicited, or is forgotten by the victim. The situation was further confused when only the basic creatinine phosphokinase (CK) measurement was available, before it could be split into muscle and heart fractions (CK-MB) and long before cardiac troponins could be measured. Now, raised levels of troponins and/or CK-MB are taken as a measure of cardiac damage, or potential damage.

#### *Decompression sickness*

The Irukandji syndrome in a diver can also resemble decompression sickness, and may present a difficult differential diagnostic problem.<sup>16</sup> There have now been a number of cases around the GBR when the Diving Emergency Service (DES) has been contacted by phone when, a short time after surfacing, a diver suddenly develops severe low back and chest pain and trouble breathing, and is distressed and restless. A high index of suspicion and careful questioning are needed. A history of a minor sting, frequently on the back of the neck, when surfacing (a small mark, often difficult to see) and/or careful differentiation of the symptoms are necessary. All this questioning may be conducted over a radiotelephone from a dive boat on the reef to the DES phone base in Adelaide – no easy task.

#### VENOM RESEARCH

Venom from *Carukia barnesi* caught in the Cairns region has been analysed and proven to be a presynaptic neuronal sodium channel agonist, strongly stimulating noradrenaline release, causing many of the clinical features of the Irukandji syndrome.<sup>30</sup> However, it is essential that other Irukandji species are caught from both the Whitsunday area and northern GBR and their venom compared *in vivo* and *in vitro* to that of *C. barnesi*. With severe hypertension and pulmonary oedema exhibited by Irukandji victims in these areas, there is obviously a potentially lethal factor in the Whitsunday Irukandji venom and that from the GBR where the second victim was stung. If antivenom can be produced it must be manipulated so that it neutralises these lethal factors, as well as the unpleasant classical effects.

#### Conclusions

Public awareness of prevention and treatment of dangerous, severe, and occasionally fatal *Chironex fleckeri* and Irukandji stings in tropical Australian waters in the summer months is lacking.<sup>31</sup> Sufficient funding is currently not available for the further research essential to develop public awareness and formulate preventive strategies. Development of effective first-aid treatment regimes for the severe systemic symptoms associated with Irukandji envenomation, including an effective antivenom against all species of Irukandji, is essential.

#### References

- 1 Southcott RV. Studies on Australian cub medusae, including a new genus and species apparently harmful to man. *Aust J Mar Freshw Res.* 1956; 7: 254–80.
- 2 Williamson JA, Fenner PJ, Burnett JW, Rifkin J, editors. *Venomous and poisonous marine animals: a medical and biological handbook.* Sydney: Surf Life Saving Australia and University of New South Wales Press Ltd; 1996.
- 3 Beadnell CE, Rider TA, Williamson JA, Fenner PJ. Management of a major box jellyfish (*Chironex fleckeri*) sting. Lessons from the first minutes and hours. *Med J Aust.* 1992; 156: 655–8.
- 4 Lumley J, Williamson JA, Fenner PJ, Burnett JW, Colquoun DM. Fatal envenomation by *Chironex fleckeri*, the north Australian box jellyfish: the continuing search for lethal mechanisms. *Med J Aust.* 1988; 148: 527–34.
- 5 Fenner PJ, Williamson JA, Blenkin JA. Successful use of *Chironex* antivenom by members of the Queensland Ambulance Transport Brigade. *Med J Aust.* 1989; 151: 708–10.
- 6 Currie B, Ho S, Alderslade P. Box-jellyfish, Coca-Cola and old wine. *Med J Aust.* 1993; 158: 868.
- 7 Burnett JW, Calton GJ. Response of the box-jellyfish (*Chironex fleckeri*) cardiotoxin to intravenous administration of verapamil. *Med J Aust.* 1983; 20: 192–4.
- 8 Ramasamy S, Isbister GK, Seymour JE, Hodgson WC. The *in vivo* cardiovascular effects of box jellyfish *Chironex fleckeri* venom in rats: efficacy of pre-treatment with antivenom, verapamil and magnesium sulphate. *Toxicon.* 2004; 43: 685–90.
- 9 Burnett JW, Calton GJ. The case for verapamil use in alarming jellyfish stings remains. *Toxicon.* 2004; 44: 817–8.
- 10 Sutherland SK, Coulter AR, Harris RD. Rationalisation of first-aid measures for elapid snakebite. *Lancet.* 1979; 1: 183–5.
- 11 Seymour J, Carrette T, Cullen P, Little M, Mulcahy RF, Pereira PL. The use of pressure immobilization bandages in the first aid management of cubozoan envenomings. *Toxicon.* 2002; 40: 1503–5.
- 12 Australian Resuscitation Council. *Marine envenomation: Guideline 8.9.6.* Melbourne: Australian Resuscitation Council; 2005.
- 13 Flecker H. 'Irukandji' stings to north Queensland bathers without production of wheals but with severe general symptoms. *Med J Aust.* 1952; 1: 89–91.
- 14 Barnes JH. Cause and effect in Irukandji stings. *Med J Aust.* 1964; 1: 897–904.
- 15 Southcott RV. Revision of some Carybdeidae (Scyphozoa: Cubomedusae), including description of the jellyfish responsible for the 'Irukandji syndrome'. *Aust J Zool.* 1967; 15: 651–71.
- 16 Hadok JC. "Irukandji" syndrome: a risk for divers in tropical waters. *Med J Aust.* 1997; 167: 649–50.

- 17 Kinsey B. *More Barnes on Box Jellyfish*. Townsville: James Cook University of North Queensland, Sir George Fisher Centre for Tropical Marine Studies; 1988. p. 115.
- 18 Little M, Mulcahy RF. A year's experience of Irukandji envenomation in far north Queensland. *Med J Aust*. 1998; 169: 638–41.
- 19 Fenner PJ, Williamson J, Callanan VI, Audley I. Further understanding of, and a new treatment for, "Irukandji" (*Carukia barnesi*) stings. *Med J Aust*. 1986; 145: 569–74.
- 20 Fenner PJ, Williamson JA, Burnett JW, Colquhoun DM, Godfrey S, et al. The "Irukandji syndrome" and acute pulmonary oedema. *Med J Aust*. 1988; 149: 150–6.
- 21 Martin JC, Audley I. Cardiac failure following Irukandji envenomation. *Med J Aust*. 1990; 153: 164–6.
- 22 Fenner P, Carney I. The Irukandji syndrome. A devastating syndrome caused by a north Australian jellyfish. *Aust Fam Physician*. 1999; 28: 1131–7.
- 23 Fenner PJ, Heazlewood RJ. Papilloedema and coma in a child: undescribed symptoms of the "Irukandji" syndrome. *Med J Aust*. 1997; 167: 650–1.
- 24 Huynh TT, Seymour J, Pereira P, Mulcahy R, Cullen P, et al. Severity of Irukandji syndrome and nematocyst identification from skin scrapings. *Med J Aust*. 2003; 178: 38–41.
- 25 Currie B, Wood YK. Identification of *Chironex fleckeri* envenomation by nematocyst recovery from skin. *Med J Aust*. 1995; 162: 478–80.
- 26 Fenner PJ, Hadok JC. Fatal envenomation by jellyfish causing Irukandji syndrome. *Med J Aust*. 2002; 177: 362–3.
- 27 Macrokanis CJ, Hall NL, Mein JK. Irukandji syndrome in northern Western Australia: an emerging health problem. *Med J Aust*. 2004; 181: 699–702.
- 28 Fenner PJ, Lewin M. Sublingual glyceryl trinitrate as prehospital treatment for hypertension in Irukandji syndrome. *Med J Aust*. 2003; 179: 655.
- 29 Corkeron MA. Magnesium infusion to treat Irukandji syndrome. *Med J Aust*. 2003; 178: 411.
- 30 Tibballs J, Hawdon G, Winkel KD, Wiltshire C, Lambert G, et al. The *in vivo* cardiovascular effects of Irukandji (*Carukia barnesi*) venom. *Proceedings of XIIIth World Congress on Animal, Plant and Microbial Toxins*. Paris: International Society of Toxinology; 2000. p. 276.
- 31 Harrison SL, Leggat PA, Fenner PJ, Durrheim DN, Swinbourne AL. Reported knowledge, perceptions, and behavior of tourists and North Queensland residents at risk of contact with jellyfish that cause the "Irukandji syndrome". *Wilderness Environ Med*. 2004; 15: 4–10.

Peter J Fenner, MD(London), MB, BS, DRCOG, FRCGP, FACTM

Associate Professor, James Cook University School of Medicine, Townsville

General Practitioner, North Mackay, Queensland

Advisor in Marine Envenomation to World Health Organisation and International Life Saving

PO Box 3080, North Mackay,

Queensland 4740, Australia

Phone: +61-(0)7-4957-7800

Fax: +61-(0)7-4957-7824

E-mail: <pjf@occupationalhealthmackay.com.au>

This paper is based on a talk by Dr Fenner at the SPUMS Annual Scientific Meeting 2004 in Noumea.

#### Acknowledgement

In a previous article by Dr Fenner entitled *Venomous marine animals (SPUMS J. 2004; 34(4): 196-202.)*, Figures 5 and 6 were courtesy of Vivien Matson-Larkin.



#### ALLWAYS DIVE EXPEDITIONS

168 High Street  
Ashburton, Melbourne

Vic. Australia 3147

TEL: (03) 9885 8863

Fax: (03) 9885 1164

TOLL FREE: 1800 338 239

<allways@bigpond.com.au>



Contact us for all your travel requirements within Australia and overseas.

Ask us about our low-cost air fares to all destinations