

Review article

Autopsy and the investigation of scuba diving fatalities

Chris Lawrence and Clive Cooke

Key words

Diving deaths, scuba accidents, snorkelling, investigations, autopsy, review article, reprinted from

Abstract

(Lawrence C, Cooke C. Autopsy and the investigation of scuba diving fatalities. *Diving and Hyperbaric Medicine*. 2006; 36: 2-8.)

The investigation of diving fatalities is multi-faceted, and the pathologist has a central and critical part to play. It is important that the pathologist has knowledge of and understands the physiological risks and possible pathological changes associated with diving, and should be aware of other facets of the investigation. This review article reproduces the guidelines for autopsy in diving accidents on the Royal Australasian College of Pathologists website (www.rcpa.edu.au).

The investigation of the diving fatality is multi-faceted, involving inquiry into a number of areas, including:

- i the past medical history of the deceased
- ii the past diving history of the deceased (including satisfactory completion of appropriate training)
- iii the circumstances of the dive (including water conditions, the dive profile, the diving techniques used, local dangers)
- iv the equipment used
- v the events before and after the fatal incident (including recent use of alcohol or drugs)
- vi the medical findings at post mortem examination of the deceased

The pathologist has a central and critical part to play. In order to interpret the autopsy findings it is important that the pathologist has knowledge of and understands the physiological risks and possible pathological changes associated with diving. Additionally, prior to the post mortem examination, the pathologist should be aware of other facets of the investigation, including the results of examination of the dive equipment used by the deceased.

It may be helpful to seek assistance from the diving physician at the local hyperbaric medicine unit, or to have undertaken one of the underwater medicine courses offered by the Royal Australian College of Anaesthetists, the Adelaide Hospital Underwater Medicine Course or the Australian Navy Underwater Medicine Course.

Diving in Australia most commonly involves self-contained underwater breathing apparatus (scuba), or snorkelling/breathhold diving. The use of surface supply breathing equipment or 'hookah' gear is common in commercial and recreational fishing and investigation of these deaths requires careful attention to previous training, examination of the settings of the equipment and review of the quality of air for carbon monoxide. Rebreather equipment is used by the military and by underwater photographers because

of the absence of expired gas bubbles. Particular risks include failure of the scrubbers to remove carbon dioxide, hypoxia and oxygen toxicity seizures when using oxygen re-breather circuits at oxygen pressures of greater than 1.5–1.8 ATA. Using pure oxygen this can occur in as little as 9 metres of sea water (msw).¹ There is also a small but rapidly growing cadre of recreational divers using rebreathers despite the dangers associated with depth and gas toxicity.² This group has had a high mortality and morbidity so far, compared with ordinary recreational diving. Commercial saturation diving and military diving present particular problems and require specialised knowledge of the practice of this kind of diving. Most of the diving fatalities are recreational scuba divers and snorkellers.

Causes of death in divers

The usual immediate cause of death is **drowning** which probably accounts for between 52 and 86 per cent of the fatalities.³ Drowning is the terminal event but it is important for the investigation to explore and identify potential underlying cause(s) (see summary):

- i inability to swim
- ii fatigue
- iii panic
 - inadequate training
- iv decreased level of consciousness
 - intoxication
 - nitrogen narcosis
 - seizures e.g., oxygen toxicity seizure
 - cerebral arterial gas embolism
 - hypercapnoea
- v natural disease – acute myocardial infarct, asthma, diabetes, epilepsy
- vi trauma
- vii entrapment in caves or wrecks
- viii physical disability
- ix equipment malfunction

In over half of the drownings in one study, there were no external signs of distress, i.e., the drowning was silent.⁴ Unfortunately, there is no diagnostic test for drowning at autopsy; it is a diagnosis of exclusion made at the end of a thorough post mortem medical examination.

Considering some of these potential underlying causes in further detail:

Decreased level of consciousness

Each 10 metres' sea water (msw) produces approximately 1 atmosphere (ATA) of pressure (i.e., at 30 msw the diver is subject to an ambient pressure of 4 ATA). During deeper dives some gases at the higher partial pressures become toxic. Nitrogen at depths of over 30 msw produces **nitrogen narcosis** (impairment of intellectual and neuromuscular function) which was reported to contribute to 9% of fatalities in ANZ studies.⁵ Divers exposed to **oxygen** at pressures of greater than 1.5–1.8 ATA for some period can suffer seizures and drowning.⁶ Similarly at depth, **carbon dioxide** retention and toxicity may depress consciousness and lead to death by drowning.

Among snorkellers, unconsciousness due to **breath holding following hyperventilation**, sometimes colloquially termed **shallow water blackout**, is a common cause of drowning. It is aggravated by the hypoxia due to ascent. The snorkeller hyperventilates then dives. During descent the increased ambient pressure maintains the partial pressure of oxygen despite consumption. However, during ascent in addition to the oxygen consumed the ambient pressure also drops, producing a very rapid drop in the partial pressure of oxygen and in oxyhaemoglobin and loss of consciousness that can result in drowning.

In divers using compressed gases, **pulmonary barotrauma and cerebral arterial gas embolism (PBT/CAGE)** probably represents the next largest group of fatalities (13–24%). Boyle's Law states that, at a constant temperature, the volume of a gas is inversely proportional to the pressure. Pulmonary barotrauma followed by cerebral arterial gas embolism (PBT/CAGE) may occur in a diver who makes an uncontrolled ascent, especially without exhaling. The volume of the gas in the lungs expands during ascent as the ambient pressure falls. If the diver does not exhale, air is forced from the airspace into the pulmonary circulation to the heart and hence into the cerebral circulation (CAGE). Pulmonary barotrauma has been reported in dives in as little as two metres of water. The history of the diver coming to the surface rapidly, crying out and then losing consciousness within seconds to minutes is characteristic of this condition. Because of the loss of consciousness there is often evidence of drowning as an agonal event. Pulmonary barotrauma less commonly causes pneumothorax; however, CL has observed a tension pneumothorax in a diver with asthma, possibly due to air trapping.

A number of deaths have occurred during **very deep dives** (50–80 msw) using compressed air. Death appears to be a consequence of loss of consciousness due to a combination of increase work of breathing, nitrogen narcosis, oxygen toxicity, hypercapnoea and possibly impaired venous return to the heart. These cases are usually brought to the surface rapidly and inevitably show significant post mortem decompression or 'off gassing'. It is important to recognise that the diver was unresponsive before ascent and that pulmonary barotrauma and cerebral arterial gas embolism (PBT/CAGE) was not the underlying problem.

Decompression sickness (the bends) is a rare cause of death in amateur divers, but a common cause of morbidity in divers. The symptoms may occur minutes to hours after the dive. Given well-developed retrieval services, deaths are rare. The bubbles that cause this process are frequently not detectable in the live patient, and would probably not be obvious at autopsy. Unfortunately, post mortem decompression or off gassing is common and is a major cause of artefactual gas at autopsy (see below).

Natural disease, particularly **ischaemic heart disease**, can cause sudden death or drowning especially in the older diver. **Asthma** is regarded by many as a contra-indication to diving. This remains a controversial issue; however, asthmatics make up around 1–2% of divers while 9% of the deaths in one ANZ series were in asthmatics.⁷ **Idiopathic pulmonary oedema** associated with scuba diving⁸ is well described in living divers and it seems reasonable that this could cause fatalities, but these cases are probably classified as drowning at autopsy.

Physical injury including head injury from boat propellers or rocks can lead to drowning. The incidents of shark attack on divers are rare but appear to be increasing.⁹ Bites from fish, eels, sea snakes, blue ringed octopus, stings from fish, cone shells, coelenterates and urchins are uncommon but should be looked for; it is doubtful if envenomation from a bite or sting may of itself explain the fatality. However, naturally the circumstances and/or the pain of the bite may result in loss of the self control required to dive safely.

Overall, the investigation of the fatality may be expected to identify multiple interacting problems that have combined to cause death. These problems usually fall into one of four groups:

- i **Medical factors** including pathology, psychology (panic, fatigue) and physiology (lack of physical fitness),
- ii **Diving techniques**, lack of air, failure to stay in visual contact with a buddy,
- iii **Equipment problems**, faults, misuse and loss of equipment, and
- iv **Environmental factors**, current, depth and visibility.

Most investigations reveal a critical error in judgement by the diver or failure to follow recommended safe diving

procedures. Commonly identified factors in Australian diving fatalities include low air or out-of-air situations (56%), buoyancy problems (over-weighted, failure to ditch weight belt) (52%), panic (39%), salt-water aspiration (37%), tidal currents or surge (36%) and fatigue (28%).¹⁰ Vomiting (10%), drugs (7%) and hypothermia, entrapment and loss of equipment such as the facemask often contribute to drowning.

Post mortem examination

1. THE HISTORY

The post mortem examination of the body of the deceased should not proceed until the pathologist is satisfied that there is a good understanding about the circumstances of the death. Naturally, there is some urgency for the post mortem examination to proceed, to minimise the amount of post mortem change obscuring important pathological findings. Accordingly, there should be open and early communication between various experts involved with the investigation – inquiry police officer; officer examining the dive equipment; police divers; dive physician.

In most cases it is useful to obtain the following before offering a final opinion as to the cause of death:

1. Police and witness statements
 - Police reports to the Coroner
 - Statements from other divers and boat crew
 - Dive profile, depth, duration, weather and current conditions of dive
 - When did the diver start to have problems? During descent, on the bottom, during ascent, after the dive.
 - Did the diver ascend rapidly?
2. Diving history of diver
 - Diving log and experience
 - Diving certification
 - Diving medical/past medical history especially ischaemic heart disease, asthma, diabetes and epilepsy
3. Examination of equipment
 - How much air is left in the tank? Composition (especially in technical diving)? Presence of carbon monoxide?
 - Regulator/tank/BC including testing under relevant conditions
 - Dive computer log down loaded (this is the best evidence of a rapid ascent)
 - Was the diver using too much weight on the weight belt?
 - Additional information should be sought if the diver was using a 'rebreather'
4. Autopsy (preferably by pathologist with experience of diving fatalities)
 - Report of X-ray or CT scan taken before autopsy

- Autopsy findings including descriptions of site and approximate volume of gas
- Histology of relevant organs especially lungs, heart and brain
- Toxicology including carbon monoxide, alcohol and drug screen

2. BODY STORAGE

The body of the deceased is often transported to the mortuary with part of the diving equipment still present – a wetsuit, fins, mask, weight belt. Because of the insulating effect of the wetsuit it is common for the body of the deceased to show early post mortem decomposition changes, despite refrigeration. The pathologist should consider reviewing and documenting appropriately (including photography) the external appearance of the body at the time of first receipt at the facility; the wetsuit may then be removed enabling satisfactory refrigeration of the body of the deceased.

3. RADIOLOGICAL EXAMINATION FOR GAS AS PART OF THE POST MORTEM EXAMINATION

Early X-ray examination of the body of the deceased should be undertaken. Important accumulations of gas may be demonstrated such as pulmonary cysts, pneumothoraces, mediastinal emphysema, intravascular gas (PBT/CAGE).

1. **CT scan** is a very sensitive way of detecting small amounts of gas in the body. It requires rapid access to a body CT scan. The CT scan will show gas in the cerebral arteries and in the right and left ventricles of the heart. Small amounts of gas in the liver are mostly a decomposition artefact.

2. **Erect X-ray of chest and abdomen** will show relatively large amounts of gas present in the right ventricle (an air-fluid level in the right ventricle or pulmonary trunk), aorta and neck veins. X-rays of the head will show gas in the cerebral vessels, while X-rays of the limbs will show gas in veins, joints and soft tissue in decomposition and post mortem off gassing.

In pulmonary barotrauma and cerebral arterial gas embolism (PBT/CAGE) you are looking for gas in the cerebral arteries and the left ventricle of the heart. Gas is also seen in the right ventricle. Finding gas in the right ventricle appears counter intuitive, however; it has been suggested that in PBT/CAGE the gas emboli pass through the capillaries and veins and become trapped in the pulmonary vein/right ventricle. Large amounts of gas can also be seen in the right ventricle in off gassing, decomposition and resuscitation.

We have used both CT scan and erect chest X-ray with success. The CT scan is more sensitive, but it can be very difficult to interpret the significance of small volumes of gas. CT or MRI scans can be useful to detect bubbles due to decompression sickness in the spinal cord.

Unfortunately the presence of intra-vascular gas is common and is not specific for PBT/CAGE. In a study of 13 diving fatalities,¹¹ intra-vascular gas was detected in 12 of the 13 cases, while only four cases had a history strongly suggestive of PBT/CAGE and three were possible CAGE.

Intra-vascular gas can also be due to:

- 1 Decomposition – the bacteria in the body produce gas after death. This can be seen in the portal/hepatic veins as little as 12 hours after death. If not refrigerated the body will show extensive gas both intra-vascular and in soft tissue within 36 hours. Hydrogen and methane in the recovered gas are an indication of decomposition, provided a gas-tight Hamilton syringe is used and no blood enters the syringe.
- 2 Resuscitation – following resuscitation with an endotracheal tube and positive ventilation, significant gas in the heart was detected in chest X-ray in 5 of 13 non-diving fatalities.¹¹
- 3 Post-mortem decompression or **off gassing** – during a deep dive the tissue absorbs nitrogen. If the diver then ascends rapidly and dies, or dies on the bottom and is brought quickly to the surface, nitrogen bubbles will form in the tissues and vessels. This process will produce both intra-vascular and soft tissue gas, and should theoretically be distinguishable from CAGE by the presence of gas in muscles and joints. In practice it is difficult to identify a PBT/CAGE in the presence of post-mortem decompression. It remains to be established how deep and how long the dive needs to be to see off gassing. Preliminary data from Townsville suggest that it may occur experimentally after 45 min at 18 msw (Griffith D, personal communication, 2005).

We do not subscribe to the view that the only thing that intra-vascular gas indicates is that the person has been diving. Detecting and measuring intra-vascular gas is important in establishing that PBT/CAGE could have occurred. However, it is necessary to have supporting evidence. The following are the criteria we use for diagnosis.

Major criteria for PBT/CAGE are:

- 1 History of a rapid ascent followed by loss of consciousness.
- 2 Gas in the left side of the heart, circle of Willis, coronary and retinal arteries.
- 3 Low probability of off gassing or decomposition.
- 4 Mediastinal or subcutaneous emphysema limited to the peri-thoracic area (e.g., supra-clavicular area) and/or pneumothorax.

Minor criteria are:

- 5 Low air or panic situation.
- 6 Student or novice divers.
- 7 Over-inflated buoyancy jacket or ditched weight belt.
- 8 Dive computer evidence of a rapid ascent.
- 9 Other evidence of barotrauma, subcutaneous emphysema or pneumothorax.

4. AUTOPSY

Once certified dead, the body of the deceased should be placed in a sealed body bag and transported as soon as possible to the autopsy site. The loss of any equipment e.g., mask, weight belt or fins should be noted. The equipment should be sealed with the valves closed to retain the breathing gas for analysis and transported as soon as possible for examination.

External examination

A conspicuous plume of white foam around the nose and mouth (pulmonary oedema fluid) is commonly seen in drowning. This may disappear quickly, so early examination of the body is essential. Compression marks around eyes/nose and small conjunctival haemorrhages usually indicate mask squeeze, suggesting inadequate equalising during descent, possibly while unconscious. Examination of the eardrum with an otoscope may show perforation (an event which usually occurs during descent). Biting of the tongue and lips may indicate fitting (also check the mouthpiece). Haemorrhagic (i.e., with bruising) abrasions and bruises on the face and limbs indicate injuries that occurred before the circulation stopped. They may include trauma due to rocks or animal bites. Post mortem injury due to animal scavenging is common around the lips and eyes and is recognised by lack of haemorrhage in the underlying tissues.

Initial dissection

Past recommendations have included initial dissection of the cranial and chest cavities underwater. Whilst opening the head and chest under running water does allow the direct demonstration of gas in the heart and vessels, **the process is cumbersome, difficult without specialised equipment, potentially dangerous to the prosector and assistant because it is hard to see and, in the end, of dubious validity** as the sawing of the skull, out of water, severs vessels which may introduce air into the venous system. The radiological demonstration of gas prior to any dissection is more reliable than either 1 or 2 below.

1. PRIMARY OPENING OF THE ELEVATED CHEST AND ASPIRATION OF THE HEART

This follows radiological documentation of gas by CT scan or erect chest X-ray.

The neck block is placed under the shoulders elevating the chest, causing the gas to collect in the superiorly positioned right ventricular outflow track and proximal aorta. The skin of the neck and chest is reflected taking care not to cut the neck veins. The sternum is removed cutting the costal cartilages with a scalpel and the pericardial sac is opened with scissors. The four chambers of the heart are then aspirated with a needle and syringe keeping the needle in the upper most point of the chamber. The volume of gas in

each chamber is recorded. Alternatively the gas can be collected under a water seal. The gas volumes are then correlated with the CT scan or X-ray findings. If gas is present the right ventricle will bulge out from the pericardial sac.

We do not test for pneumothorax, as past experience indicates that it is uncommon in diving fatalities and if present, will usually show up on the erect chest X-ray or CT scan.

2. DISSECTION UNDER WATER

The scalp is incised then reflected under running water, the skull is cut carefully avoiding cutting the dura and the brain is removed underwater (see "Post mortem Technique in Fatal Diving Accidents". Royal College of Pathologists of Australasia Broadsheet No.27).

The chest can be opened underwater, or the heart can be opened after filling the opened pericardial sac with water.

Head and neck

If the chest is opened before the head, the carotid arteries should be tied off at the base of the neck. The head is opened and the presence of air in the cerebral arteries and dural veins is noted.

The middle ears can be removed, fixed in formalin then decalcified and serially sectioned to show damage to the middle and inner ear. An ENT surgeon may appreciate the opportunity to assist with this examination. Given concerns regarding tissue retention, in practice, we now examine the eardrum using an otoscope and leave the middle ear intact, unless there is other evidence of a significant middle or inner ear problem – it should be recognised, however, that this approach may miss potentially important middle and inner ear pathology.

Formal neuropathology examination of the brain is advisable (and of the spinal cord if spinal decompression sickness is suspected). In some PBT/CAGE cases, there are occasional small perivascular haemorrhages in the brainstem on the floor of the fourth ventricle, of uncertain significance. The minimum time for formalin fixation of the brain to enable optimal neuropathology examination appears to be about 48 hours' immersion in 20% formalin. If, for local reasons, the Coroner (or other legislated authority) is not prepared to authorise brain retention for formal neuropathology examination, then examination of the fresh brain should nonetheless proceed in the same systematic and careful manner – the small perivascular haemorrhages of PBT/CAGE are still identifiable. Naturally, where resuscitation is initially successful and the diver survives for some time, the likelihood of identifying pathological changes in the brain and spinal cord increases.

Chest and abdomen

The finding of air in the heart, inferior vena cava and portal vein are described above.

Over-expanded lungs that cover the heart and show the impressions of the ribs may be seen with drowning and in conditions where there is peripheral air trapping such as asthma and deep aspiration of vomitus; this may also be a feature of respiratory resuscitation.

Water in the stomach and florid pulmonary oedema in the trachea and lungs also suggest drowning.

The lungs can be inflated with air underwater to find air leaks that suggest pulmonary barotrauma. Where indicated, inflation of the whole lungs with formalin allows detailed examination for apical bullae with associated haemorrhage in an otherwise normal lung. This may be the source of an unexpected PBT/CAGE.

The heart should be examined closely for coronary atherosclerosis and other cardiac anomalies which can cause sudden death.

The foramen ovale of the heart should be tested for probe patency as this may give rise to paradoxical air emboli.

Musculo-skeletal system

In long term and commercial divers we have in the past examined the femoral head, but found no pathology. With X-rays of the joints we tend now only to examine if the joint appears radiologically abnormal.

Histology

Comprehensive microscopic examination of all organs should be undertaken.

Divers who are kept alive for some hours may show significant pathology in the heart and central nervous system including small infarcts in the cardiac muscle and spinal cord.

Other tests

Preserved blood and urine should be submitted for alcohol, a drug screen and carbon monoxide.

There is no reliable test for drowning.

Diatoms remain the best chance for a diagnostic test for drowning; however the test is not routinely available, as it requires working with concentrated acid and experience in distinguishing the species of diatom. A sample of water from the site, blood, bone marrow, kidney and lung should be collected if this test is contemplated.

Comparison of chloride levels in right and left ventricular blood has fallen into disrepute. In a salt-water drowning sampled soon after death where no cardiopulmonary resuscitation occurs there will sometimes be a 17mmol.l⁻¹ increase in the left ventricle chloride level.

Acknowledgement

We would like to thank Carl Edmonds for his help, guidance and inspiration over the past decade and Jim Caruso for his notes (Caruso J L, Bell M. The medicolegal investigation of a recreational diving fatality. *American Academy of Forensic Science Workshop*, 2002) and his insights.

References

- 1 Pennefather J. Diving equipment. In: Edmonds C, Lowry C, Pennefather J, Walker R (eds). *Diving and subaquatic medicine*. 4th edition. London: Arnold Publishing; 2002. p. 42.
- 2 Lawrence CH. A diving fatality due to oxygen toxicity during a "technical" dive. *Med J Aust*. 1996; 165: 262-3.
- 3 Edmonds C. Why divers die: the facts and figures. In: Edmonds C, Lowry C, Pennefather J, Walker R (eds). *Diving and Subaquatic Medicine*. 4th edition. London: Arnold Publishing; 2002. p. 477.
- 4 Edmonds C. Drowning syndromes: saltwater aspiration syndrome. In: Edmonds C, Lowry C, Pennefather J, Walker R (eds). *Diving and subaquatic medicine*. 4th edition. Arnold Publishing: London; 2002. p. 279.
- 5 Edmonds C. Why divers die: the facts and figures. In: Edmonds C, Lowry C, Pennefather J, Walker R (eds). *Diving and subaquatic medicine*. 4th edition. Arnold Publishing: London; 2002. p. 474.
- 6 Lowry C. Oxygen toxicity. In: Edmonds C, Lowry C, Pennefather J, Walker R (eds). *Diving and subaquatic medicine*. 4th edition. London: Arnold Publishing; 2002. p. 208.
- 7 Edmonds C. Why divers die: the facts and figures. In: Edmonds C, Lowry C, Pennefather J, Walker R (eds). *Diving and subaquatic medicine*. 4th edition. Arnold Publishing: London; 2002. p. 481.
- 8 Slade JB, Hattori T, Ray CS, Bove AA, Cianci P. Pulmonary oedema associated with scuba diving: case reports and review. *Chest*. 2001; 120: 1686-94.
- 9 Edmonds C. Trauma from marine creatures. In: Edmonds C, Lowry C, Pennefather J, Walker R (eds). *Diving and subaquatic medicine*. 4th edition. London: Arnold Publishing; 2002. p. 330.
- 10 Edmonds C. Why divers die: the facts and figures. In: Edmonds C, Lowry C, Pennefather J, Walker R (eds). *Diving and subaquatic medicine*. 4th edition. Arnold Publishing: London; 2002. p. 477-81.
- 11 Lawrence C. Interpretation of gas in diving autopsies. *SPUMS J*. 1997; 27: 228-30.

This Guideline has been prepared by:

Dr Chris Lawrence, MB BS, FRCPA, is Director, Statewide Forensic Medical Services

*4th Floor H Block, Royal Hobart Hospital,
Liverpool St, Hobart, TAS, Australia 7017
and*

Dr Clive Cooke, BMedSci, FRCPA, is Chief Forensic Pathologist and Clinical Director of Forensic Services, PathCentre, WA

Radiology images courtesy of Dr Robin Harle, Department of Radiology, Royal Hobart Hospital, Hobart, Tasmania.

and is endorsed by The Royal College of Pathologists of Australasia (RCPA).

Reprinted with minor editing from the RCPA website (www.rcpa.edu.au) with the kind permission of the authors and the RCPA.

Summary of features of the common causes of death

(i) Drowning

- | | |
|-----------|--|
| Equipment | - Leaking or poorly maintained equipment
- Loss of equipment e.g., mask, fins
- Carbon monoxide in air mix
- Faulty CO ₂ scrubber in a rebreather
- Technical diving use of hypoxic bottom mix on the surface or oxygen-enriched mixtures at depth |
| Autopsy | - Pulmonary oedema fluid in mouth, trachea and lungs
- Over-expanded lungs covering the heart, with impressions of the ribs
- Salt water in the stomach (check sodium and chloride levels)
- The amount of water inhaled may be variable. Dry drowning is in our experience rare in salt water. |

(ii) Pulmonary barotrauma/cerebral arterial gas embolism (PBT/CAGE)

- | | |
|-----------|---|
| History | - Inexperienced diver, out of air, night dive, panic situation
- Rapid ascent followed by sudden loss of consciousness |
| Equipment | - Rapid ascent on dive profile downloaded from dive computer |
| CT scan | - Gas in the left ventricle and cerebral arteries
- Mediastinal emphysema
- Pulmonary barotrauma |
| Autopsy | - Gas in the left ventricle and cerebral arteries
- Bullae and dilated airspaces with haemorrhage in the lungs |

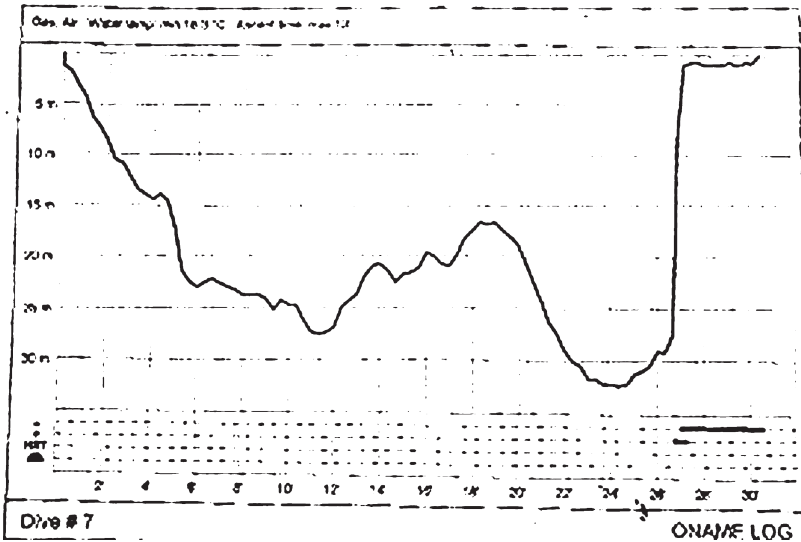


Figure 1
 Dive profile downloaded from dive computer. The diver attempted to breathe from buddy's buoyancy compensator then ascended 29 metres in 20 seconds, surfaced coughing and became unconscious. Cause of death was pulmonary barotrauma/cerebral arterial gas embolism (PBT/CAGE).

Figure 2

This X-ray is of a diver who died after a 43 msw rebreather dive. He was found on the bottom with his mask off shortly after leaving the surface. He had set his equipment incorrectly and had a P_iO_2 at depth well in excess of 202 kPa. His rescuer put an octopus regulator in his mouth and purged gas into him all the way to the surface. Gas-fluid levels are seen in the heart and gastro-intestinal tract.

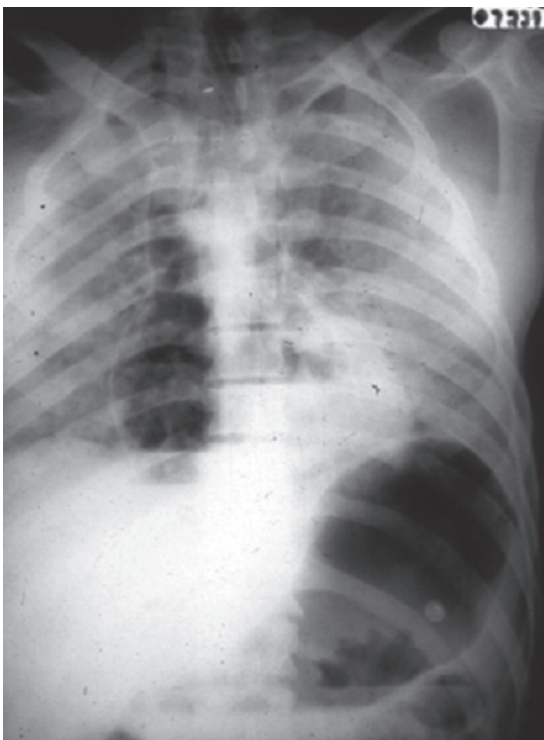


Figure 3

CT scan of chest and brain showing gas in the left ventricle and right middle cerebral artery in a diver who had separated from his buddy, was low on air and ditched his weight belt. The ascent was unwitnessed but the history and findings together suggested pulmonary barotrauma, with cerebral arterial gas embolism (PBT/CAGE).

