

Case report

Diving-related pulmonary oedema as an unusual presentation of alcoholic cardiomyopathy

Helen Kenealy and Kenneth Whyte

Key words

Immersion, pulmonary oedema, scuba diving, cardiovascular, exogenous poison, case reports

Abstract

(Kenealy H, Whyte K. Diving-related pulmonary oedema as an unusual presentation of alcoholic cardiomyopathy. *Diving and Hyperbaric Medicine*. 2008; 38: 152-4.)

Diving-related pulmonary oedema (DRPO) is an uncommon and incompletely understood phenomenon. Pulmonary oedema has been rarely documented in shallow water. It is also associated with cold water and exertion and has been seen in swimmers as well as divers with no underlying heart disease. We describe an otherwise well 69-year-old lady who developed diving-related pulmonary oedema on her second and third dives in a shallow, heated pool. Follow-up echocardiogram revealed moderate global left ventricular dysfunction with an ejection fraction of 37%. There was a history of alcohol consumption of half a bottle of wine per day, which combined with the echocardiographic findings led to the diagnosis of alcoholic cardiomyopathy. We believe this not only to be the oldest patient with a documented case of DRPO but also the first report where it has clearly unmasked clinically significant underlying heart disease.

Introduction

Pulmonary oedema is a rare and probably under-reported, diving-related event with only infrequent reports in the literature since the first report in 1981. However, the pathophysiological mechanism remains elusive. To date this phenomenon has been reported only in patients with no evidence of underlying cardiac disease.

Case history

Mrs A was a previously fit and well 69-year-old lady. She originally denied any exertional dyspnoea in the period preceding her decision to start diving. In retrospect, she reported some minor exertional dyspnoea in the preceding months; however, she had not felt it sufficient to be of significance. Her only past medical history was that of treated hypothyroidism. Her social history was significant in that she was still working and consumed half a bottle of wine per day. She had no previous history to suggest ischaemic heart disease.

She presented with a history that, at her second diving lesson one week prior, she had developed chest tightness and dyspnoea following ascent from four metres' depth. This first episode was not severe and settled within 24 hours. No medical attention was sought.

On her third dive, she had successfully ascended without difficulty midway through the lesson in a chlorinated pool heated to 28°C. She then descended again for the duration of the lesson. At the end of the lesson she had to swim underwater the entire length of an Olympic-sized swimming

pool (50 metres) to ascend near steps. On this second ascent, she noted marked shortness of breath and chest tightness. Onlookers described her as being blue.

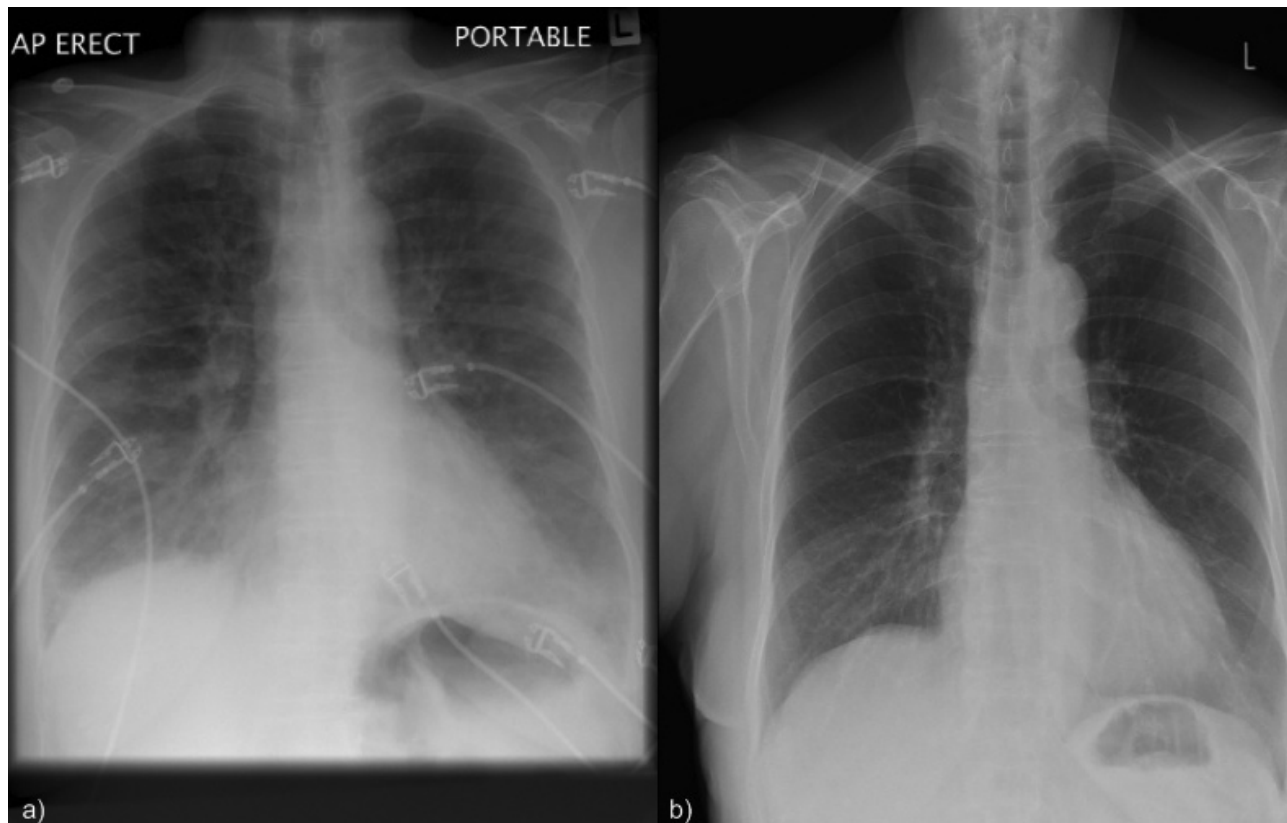
On initial medical assessment, she was hypotensive and in acute pulmonary oedema. There was a left bundle branch block on electrocardiogram (ECG), which was presumed to be new as there were no previous ECGs to compare with. Symptoms improved with oxygen, intravenous frusemide and morphine. Initial chest X-ray showed unequivocal pulmonary oedema (Figure 1a).

Subsequently in-patient angiography showed only mild coronary artery disease. Echocardiogram revealed global systolic dysfunction with an ejection fraction of 45% and no regional wall motion abnormalities. Fasting glucose was normal, fasting cholesterol mildly elevated. Her renal function was normal. Repeat chest X-ray showed resolution of pulmonary oedema (Figure 1b). No troponin rise was noted; B-type natriuretic peptide was not performed. Spirometry as an inpatient was normal with a forced expiratory volume in one second of 2.76 litres (112% of predicted) and forced vital capacity of 3.25 litres (106% of predicted).

In this case, we strongly recommended that she never dive again. She has been followed up by the cardiology service and has not dived again. Her repeat echocardiogram, however, revealed a mildly dilated left ventricle with abnormal septal motion consistent with persisting left bundle branch block. There was evidence of ongoing moderate global left ventricular dysfunction with a calculated ejection fraction of 37%. The left ventricular diastolic parameters

Figure 1

Figure 1a is a portable chest X-ray taken on arrival at the emergency department, demonstrating pulmonary oedema. Figure 1b is a follow-up chest X-ray a day later after treatment with intravenous frusemide.



were consistent with abnormal left ventricular relaxation with mildly increased end-diastolic pressure. There were no valvular or right-sided abnormalities noted.

She continues to have symptoms of shortness of breath on exertion consistent with NYHA class II. It is now considered that her diving-related pulmonary oedema (DRPO) was an unusual presentation of a mild, occult alcoholic cardiomyopathy.

Discussion

PATHOPHYSIOLOGY

Pulmonary oedema is thought to be a rare complication of diving.¹ The mechanism is not completely understood. The first case series was published in 1981 by Wilmhurst et al.² They described 11 divers in cold British waters who developed pulmonary oedema. The proposed mechanism was that of increased peripheral vascular resistance due to cold exposure thus raising both preload and afterload. They showed that healthy controls did not show the same degree of increased vascular resistance in the forearm when exposed to cold stimulus as those that developed pulmonary oedema. However, this finding was not replicated in a further study.¹ Cases arising from warm-water diving have been reported, shedding doubt on the causative role of cold water in the development of DRPO.³

There have since been reports of pulmonary oedema while swimming (not diving) in cold waters.⁴ Studies in military personnel suggest there is an association with strenuous activity.^{1,3} Immersion in water leads to redistribution of blood and an increase in pulmonary capillary pressure, thus increasing the risk of pulmonary capillary leak. Cold immersion is thought to increase this redistribution of blood.¹ Although cold may be a risk factor because it increases peripheral vascular constriction and thus cardiac preload and afterload, it is clear that cold-water diving is not a pre-requisite for DRPO.

It appears that multiple factors may contribute to the risk of DRPO and in any individual a complex interaction of factors may precipitate an episode of DRPO.

DEMOGRAPHICS AND DIVE CHARACTERISTICS

Cases reported in the literature number over 30 as described in a recent review.⁵ The cases have ranged in age from 23 to 61, mean ages have been quoted as 43.3 years and 45.6 years.^{1,6-8} The water temperatures have ranged from approximately 0°C⁶ to 25°C.^{6,9} The diving depths range from 3.3 to 42 metres' sea water.^{1,9}

DRPO is thought to be under reported given that spontaneous recovery has been observed to occur, as probably occurred in our patient during her second diving lesson the previous

week.⁵ Symptoms often resolve with supportive treatment only once patients are removed from the water, such that diuretics are not always necessary.

DRPO AND CARDIAC DISEASE

Our patient is the first unequivocal report of DRPO unmasking underlying cardiac disease, in her case a probable alcoholic cardiomyopathy. There has been one case reported in a series by Hampson et al in which a 60-year-old lady with pre-existing hypertension developed DRPO and was found to have mitral valve prolapse with mitral regurgitation on echocardiogram.⁷ She had normal left ventricular systolic function and successfully completed seven subsequent dives in waters of approximately 25°C with a wetsuit. In this case we would suggest that the role, if any, of her mitral valve disease in the development of DRPO was uncertain.

During a dive the water pressure on the thoracic cage alters chest wall compliance, pooling of blood in the lungs alters the lung compliance and gas density increases airway resistance. These factors result in the need to generate a more negative pleural pressure to maintain tidal volume. This will, in turn, lead to a higher pressure gradient across the left ventricular (LV) wall, which results in increased LV wall stress and work – in contra-distinction to the effect of CPAP in acute pulmonary oedema where the positive pressure decreases the pressure gradient across the LV and hence reduces the LV wall stress and work.^{10,11} We postulate that the additional load imposed on the LV during these dives by the effect of immersion on both central vascular pressures and on the LV transmural pressure precipitated pulmonary oedema in our patient.

LIKELIHOOD OF RECURRENCE AND RETURN TO DIVING

These reports indicate that some but not all will have recurrence of symptoms when re-challenged.^{1,3} There is no way to predict who will or will not re-develop symptoms. Slade et al reported a case series of eight middle-aged divers with DRPO.⁶ Their subjects ranged from people doing their first dive to very experienced divers. Subsequently three of their patients successfully resumed diving.

Tetzlaff and Thorsen support the practice of advising sufferers to not dive again.⁵ For those who will not follow this advice, there is anecdotal evidence in 15 cases that a 5 mg dose of nifedipine taken orally before a dive may prevent recurrent attacks.¹² During follow-up, it has been shown that most patients with DRPO will develop systemic hypertension.⁸ In our patient we believe the underlying cardiomyopathy would make further attempts at diving hazardous for the reasons outlined above.

Disclaimer

We declare no conflicts of interest. The authors are salaried

employees and no additional funding was provided for this article.

References

- 1 Pons M, Blickenstorfer D, Oechslin E, Hold G, Greminger P, et al. Pulmonary oedema in healthy persons during scuba diving and swimming. *Eur Respir J.* 1995; 8: 762-7.
- 2 Wilmshurst P, Nuri M, Crowther A, Betts J, Webb-Peploe MM. Forearm vascular response in subjects who develop recurrent pulmonary oedema when scuba diving: a new syndrome. *Br Heart J.* 1981; 45: 349.
- 3 Weiler-Ravell D, Shupak A, Goldenberg I, Halpern P, Shoshani O, et al. Pulmonary oedema and haemoptysis induced by strenuous swimming. *BMJ.* 1995; 311: 361-2.
- 4 Mahon RT, Kerr S, Amundson D, Parrish JS. Immersion pulmonary oedema in Special Forces combat swimmers. *Chest.* 2002; 122: 383-4.
- 5 Tetzlaff K, Thorsen E. Breathing at depth: physiologic and clinical aspects of diving while breathing compressed gas. *Clin Chest Med.* 2005; 26: 355-80.
- 6 Slade JB, Hattori T, Ray CS, Bove AA, Cianci P. Pulmonary oedema associated with scuba diving. *Chest.* 2001; 120: 1686-94.
- 7 Hampson NB, Dunford RG. Pulmonary oedema of scuba divers. *Undersea Hyperb Med.* 1997; 24: 29-33.
- 8 Wilmshurst PT, Nuri M, Crother A, Crowther WA, Webb-Peploe MM. Cold induced pulmonary oedema in scuba-divers and swimmers and subsequent development of hypertension. *Lancet.* 1989; 1: 62-5.
- 9 Gnadinger CA, Colwell CB, Knaut AL. Scuba diving-induced pulmonary oedema in a swimming pool. *J Emerg Med.* 2001; 21: 419-21.
- 10 Buda AJ, Ingels NB, Daughters GT, Stinson EB, Alderman EL. Effect of intrathoracic pressure on left ventricular performance. *New Eng J Med.* 1979; 301: 453-9.
- 11 Bersten AD, Holt AW, Vedig AE, Skowronski GA, Baggoley CJ. Treatment of severe cardiogenic pulmonary oedema with continuous positive airway pressure delivered by face mask. *New Eng J Med.* 1991; 325: 1825-30.
- 12 Wilmshurst P. Cardiovascular problems in divers. *Heart.* 1998; 80: 537-8.

Submitted: 24 June 2008

Accepted: 25 July 2008

Helen Kenealy, MBChB, is Respiratory Registrar and Kenneth Whyte, MD, FRACP, FRCP(Glasg), is Respiratory Physician at the Green Lane Respiratory Medicine Service, Auckland Hospital, New Zealand.

Address for correspondence:

*Helen Kenealy
Green Lane Respiratory Medicine Service
Level 7, Support Building, Auckland City Hospital
Park Road, Grafton, Auckland 1023
New Zealand*

Phone: +64 (0)9-307-4949

Fax: +64-(0)9-631-0770

E-mail: <hdkenealy@gmail.com>