

Cutis marmorata in decompression illness may be cerebrally mediated: a novel hypothesis on the aetiology of *cutis marmorata*

Tom CPM Kemper, Rienk Rienks, Pieter-Jan AM van Ooij and Rob A van Hulst

Abstract

(Kemper TPCM, Rienks R, van Ooij PJAM, van Hulst RA. *Cutis marmorata* in decompression illness may be cerebrally mediated: a novel hypothesis on the aetiology of *cutis marmorata*. *Diving and Hyperbaric Medicine*. 2015 June;45(2):84-88.)

Introduction: Cutaneous decompression sickness (DCS) is often considered to be a mild entity that may be explained by either vascular occlusion of skin vessels by bubbles entering the arterial circulation through a right-to-left shunt or bubble formation due to saturated subcutaneous tissue during decompression. We propose an alternative hypothesis.

Methods: The case is presented of a 30-year-old female diver with skin DCS on three separate occasions following relatively low decompression stress dives. Also presented are the findings of cutaneous appearances in previously reported studies on cerebral arterial air embolism in pigs.

Results: There was a close similarity in appearance between the skin lesions in this woman (and in other divers) and those in the pigs, suggesting a common pathway.

Conclusions: From this, we hypothesize that the cutaneous lesions are cerebrally mediated. Therefore, cutaneous DCS might be a more serious event that should be treated accordingly. This hypothesis may be supported by the fact that *cutis marmorata* is also found in other fields of medicine in a non-diving context, where the rash is referred to as *livedo reticularis* or *livedo racemosa*. These are associated with a wide number of conditions but of particular interest is Sneddon's syndrome, which describes the association of *livedo racemosa* with cerebrovascular events or vascular brain abnormalities. Finally, there is a need for further research on the immunocytochemical pathway of cutaneous DCS.

Key words

Decompression sickness; cerebral arterial gas embolism (CAGE); decompression illness; patent foramen ovale (PFO); case reports; animal model; hypothesis

Introduction

Decompression illness (DCI) describes a range of symptoms and signs caused by a rapid reduction in environmental pressure, which results in the formation of intravascular or extravascular gas bubbles.¹ Symptoms range from skin itching and joint pain to severe neurological signs, cardiac collapse and death.¹ Cutaneous symptoms, also referred to as 'skin bends',² may manifest as two very distinct morphological rashes. One is the more common, fine erythematous, itchy rash, often difficult to differentiate from sunburn, and not usually associated with progress to more serious symptoms. The second is the more typical marble-like rash called *cutis marmorata*, also referred to as *livedo reticularis* (Figure 1).¹

Rapid reduction in environmental pressure can occur during ascent after diving or exposure to a hypobaric environment by flying to high altitudes. DCI comprises two pathophysiological syndromes; arterial gas embolism (AGE) and decompression sickness (DCS). AGE can be caused by rupture of alveolar capillaries as a result of gas expansion in alveoli and result in air bubbles entering the arterial circulation. Also, venous gas emboli may result in AGE by entering the arterial circulation through a right-to-left shunt.¹ Furthermore, AGE can be iatrogenically inflicted and is described in mechanically ventilated patients.³ Another rare form of AGE is described in airplane passengers with pre-existing lung pathologies, most commonly in the form of intra-pulmonary air-filled cysts.^{4,5}

The other pathophysiological phenomenon of DCI is the more common DCS which is caused by in-situ bubble formation of dissolved inert gas, such as nitrogen.¹ DCS has traditionally been classified into two further sub-types: Type 1 with musculoskeletal pain, cutaneous symptoms, including pain, cutaneous manifestations and constitutional symptoms and Type 2, which may include vestibular, neurological and pulmonary symptoms.¹ In cutaneous DCS, the typical *cutis marmorata* is believed to be caused by vascular occlusion of skin vessels by peripheral gas bubbles in the subcutaneous tissues, and is reported to be more likely to be associated with a right-to-left shunt. The hypothesis is that venous gas bubbles enter the arterial circulation through a right-to-left shunt and, in turn, cause vascular occlusion of the peripheral skin vessels.⁶ Interestingly, multiple reports of AGE have often described *cutis marmorata* as an associated clinical finding.³⁻⁵

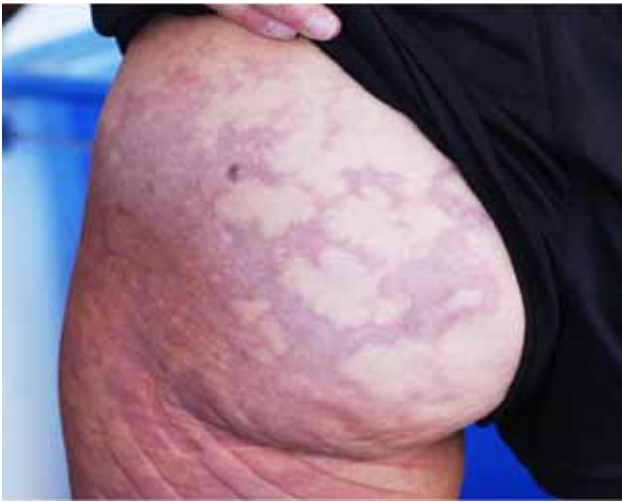
We propose a new hypothesis for the aetiology of *cutis marmorata*. This is illustrated with a case report of a diver with 'undeserved' DCI, who underwent cardiologic screening for a right-to-left shunt, and an animal study of AGE.

Case report

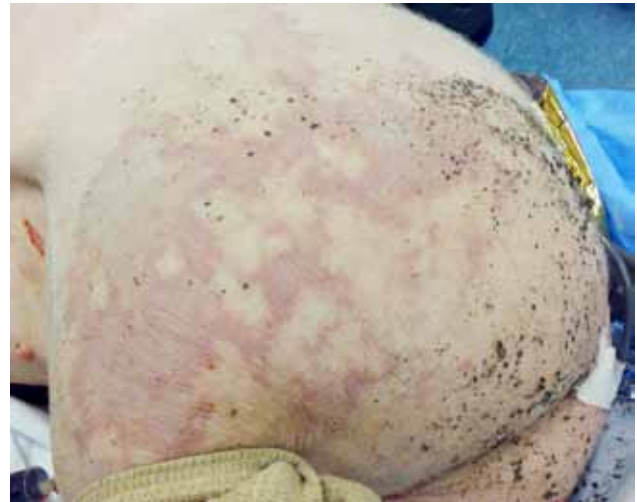A 30-year-old, female scuba diver was referred to our hospital for further analysis after suffering DCS. Patient history was suspect for three episodes of cutaneous DCS. The first episode was in 2008 after a dive to 30-metres

Figure 1

Cutis marmorata, in a scuba diver
(courtesy Richard Moon MD, with permission)

**Figure 2**

Cutis marmorata in a swine 4 min after introducing an air bubble into the arterial brain circulation



depth. Thirty minutes after the dive, the patient experienced intense itching with the formation of red spots spreading from the shoulder to the chest and the legs; the symptoms completely disappeared after breathing 100% oxygen. All three dives were inconsequential and she was diagnosed as having had 'undeserved' DCS. She exhibited no cardiac risk factors, including no smoking or alcohol consumption. Transoesophageal echocardiography was performed which demonstrated the presence of a type II atrial septum defect (ASD). As this has been associated with DCS,⁶ she was advised against diving, and the possibility of closure of the ASD was discussed.

Animal study

Our group has had extensive experience since 2000 with ethical committee-approved studies on cerebral arterial gas embolism (CAGE) and its effects on brain metabolic function in anaesthetised pigs, using air injection into the internal carotid artery and continuous measurement with multiparameter sensors and microdialysis.⁷ It was concluded that CAGE has a deleterious effect on intracranial pressure and brain metabolism. An interesting secondary observation has been that within minutes of introducing bubbles into the brain circulation, a typical mottled rash appeared on the skin of the pigs (Figure 2), which bore a striking resemblance to the skin rashes found in human DCS (Figure 1). In a recent study reported in 2013, all 22 pigs suffering CAGE developed this skin rash.⁸ The amount of air injected was found to have no additional influence on the development or severity of the skin rash.

Discussion

It is suggested that *cutis marmorata* is caused by the presence of nitrogen bubbles in the subcutaneous tissues and blood vessels as a result of decompression, which causes vascular

congestion and an inflammatory response.^{9,10}

Our human case report is consistent with the finding of a significant relationship between cutaneous DCI and the presence of a cardiac right-to-left shunt.⁶ The authors concluded that cutaneous DCI may be explained by two pathophysiological mechanisms. First, DCI is usually associated with a large right-to-left shunt and it was hypothesised that the marbled appearance of the skin is caused by vascular occlusion of skin vessels. The gas bubbles are thought to enter the arterial circulation via the cardiac shunt causing a paradoxical gas embolism with peripheral amplification when the bubble emboli invade tissues supersaturated with inert gas. However, why such a large area of skin is affected by the occlusion of only a few skin vessels could not be explained. The second possible pathophysiological mechanism focuses on individuals without a shunt, where bubbles pass through an overloaded lung filter or where autochthonous bubbles form in situ is postulated as the most likely mechanism.

We propose an alternative pathophysiological mechanism for developing *cutis marmorata*. Our experiments in swine show that it occurs within minutes after introducing a single gas bolus into the arterial brain circulation. We speculate on a pathway where the presence of an intracranial gas embolism gives rise to the release of neuropeptides, which initiates an inflammatory response. There is evidence that many neuropeptides are localised in the skin, where they are released from sensory nerves, producing several features of acute and chronic inflammation such as vasodilatation, plasma extravasation and production of cytokines.^{11,12} However, a weakness of our hypothesis is the lack of immunocytochemical information from our animal studies.

In an investigation of the histopathology and ultrastructure of cutaneous lesions in swine after decompression, the lesions

were biopsied and histological abnormalities were found in 91% of the biopsies.¹³ The most common finding was vascular congestion and in 45% of the lesions, focal areas of vasculitis were noted. Perivascular neutrophil infiltrates, oedema and occasional haemorrhage were also found. All biopsied skin lesions showed ultrastructural abnormalities, with acute inflammation affecting the dermal vasculature as the most common finding.

In contrast to the hypothesis of Wilmshurst et al,⁶ this pathophysiological mechanism may explain why such a widespread area of the skin is affected, since the skin lesions may be explained by a centrally-mediated inflammatory response. However, we cannot rule out the possibility of the gas bubble migrating through the brain circulation and re-entering the body's arterial system via venous return and through the intra-cardiac right-to-left shunt, resulting in peripheral gas emboli. Nevertheless, the speed at which the skin changes in the pigs occurred is more suggestive of a centrally-mediated response rather than a re-circulating gas embolism. Furthermore, this mechanism supports other studies showing that the presence of *cutis marmorata* may be a prelude to more severe illness involving the central nervous system or cardiovascular system,^{13,14} since we believe that *cutis marmorata* may be associated with intracranial gas emboli, most likely accompanied by a congenital heart defect.

Of interest is the fact that *cutis marmorata* is also found in other fields of medicine in a non-diving context, where the typical skin manifestations are referred to as *livedo reticularis* or *livedo racemosa*; these two terms are often used interchangeably and both entities are more often referred to as *livedo reticularis*. Although used interchangeably, it is of clinical importance to differentiate between the two entities.¹⁵ *Livedo reticularis* is a striking, macular, violaceous, net-like, patterned erythema of the skin and can be differentiated into four entities based on the duration of the rash and its association with temperature.¹⁶ The four entities consist of physiologic, primary, idiopathic and amantadine-induced *livedo reticularis*.¹⁶ Physiologic *livedo reticularis* most often affects young women and is commonly found on the legs as a result of cold exposure. The mottling of the skin is caused by impairment of the blood flow in cutaneous vessels and usually resolves on re-warming of the skin.¹⁶ Primary *livedo reticularis* (also with a fluctuating course) differs from physiologic *livedo reticularis* in that it is unrelated to ambient temperature. In contrast to physiologic and primary *livedo reticularis*, the idiopathic form is persistent and diagnosed when no other pathological signs are found.¹⁶ This last form is amantadine-induced *livedo reticularis* and (as the name suggests) is caused by the use of the synthetic antiviral agent amantadine, which is used for the treatment of Parkinson's disease and symptoms of multiple sclerosis.¹⁶

Livedo racemosa is characterised by a striking, violaceous, net-like patterning of the skin, similar to *livedo reticularis*,

but is more widespread and generalised. In contrast to *livedo reticularis*, which typically occurs on the limbs, it is also found on the trunk and/or buttocks.¹⁶ *Livedo racemosa* also differs in shape; instead of a regular, net-like patterning as found in *livedo reticularis*, it is characterised by irregular, broken, circular segments.¹⁵ Moreover, *livedo racemosa* is associated with a number of disorders including antiphospholipid syndrome, livedoid vasculopathy, systemic lupus erythematosus, essential thrombocythaemia, thromboangiitis obliterans, polycythaemia rubra vera, polyarteritis nodosa and Sneddon's syndrome.¹⁶ Although *cutis marmorata* is often referred to as *livedo reticularis*, the skin findings in DCI and in our study animals show more similarities with *livedo racemosa* with regard to morphology and localisation.

Of particular interest is Sneddon's syndrome, which is characterised by the combination of cerebrovascular events and widespread *livedo racemosa*.¹⁷ In this syndrome, the *livedo racemosa* may precede the onset of stroke by years and can be located on the limbs, trunk, buttocks, face, or the hands or feet. The trunk and buttocks are involved in nearly all patients and *livedo racemosa* is noticed in more than half of the patients before cerebrovascular incidents.¹⁷ In some patients, the rash is first detected at the time of stroke occurrence and, in rare cases, it appears after neurological symptoms.¹⁷ Since the rash in some patients with Sneddon's syndrome is present for years in the absence of neurologic symptoms, precluding the first cerebrovascular event, it is plausible, considering our hypothesis, that the formation of *cutis marmorata* after suffering DCI is associated with subclinical brain damage in the absence of neurological signs or symptoms.

Sneddon's syndrome was originally considered to be a clinical diagnosis but is now regarded as a manifestation of different disease entities and can be divided into three different forms.¹⁷ The first form is primary Sneddon's syndrome and is considered as Sneddon's syndrome without an identifiable causative factor. The second is an autoimmune form in association with antiphospholipid antibodies or coexisting systemic lupus erythematosus. The third is associated with a thrombophilic form.¹⁷ The pathophysiology of Sneddon's syndrome remains incompletely understood, although the association with antiphospholipid antibodies suggests that the symptoms are secondary to a thrombotic process.¹⁷ Although thrombosis may play a role in the pathogenesis of Sneddon's syndrome it is unclear how it occurs in antiphospholipid negative cases. Since heart valve abnormalities are also a common finding in Sneddon's syndrome, with a total prevalence similar in both antiphospholipid positive and negative cases, it is thought that an embolic mechanism may play an important role in the occurrence of neurologic and even skin manifestations.¹⁷ Because some patients appear to be antiphospholipid-negative and lack other coagulation deficits, it is thought that the primary vasculopathy is the pathophysiologic change in Sneddon's syndrome and that the

non-vasculitic small and medium-sized vessel arteriopathy (as found in brain biopsies) may be the cause of both skin symptoms and cerebrovascular events. However, the type and origin of the arteriopathy remains largely unknown.¹⁷

The occurrence of *cutis marmorata* after inflicting a cerebral embolic event in our study animals, and the presence of *livedo reticularis* in association with cerebrovascular accidents in other clinical syndromes, may suggest that the typical skin rash has a similar common pathway in the brain. This could also explain why the livedo occurs in patients without coagulation deficits, since the skin rash may be centrally induced. This hypothesis is possibly supported by the case report of a 19-month-old girl who developed *livedo reticularis* during a second cerebrovascular event only a few weeks after a first event.¹⁸ The event presented itself as right-sided hemiparesis and lethargy and was found to be a result of subacute ischaemic changes in the left frontoparietal white matter on MRI scanning. No thrombosis was identified but the vascular pattern was consistent with Moyamoya disease. No primary coagulation deficit could be identified. This latter case also illustrates the development of a livedo rash associated with intracranial vascular changes in the absence of a coagulation deficit.

We hypothesise that a common pathway in the brain may play a role in the development of the typical skin changes found in both DCI and other clinical entities associated with *livedo reticularis*. Although the exact mechanism remains unclear, we postulate a mechanism in which bubbles or bubble-related effects (oedema, inflammation) in the brain give rise to the release of neuropeptides and, in turn, cause an inflammatory response in the skin. We believe that additional experiments in which immunocytochemical measurements are performed may provide additional evidence to support this hypothesis and further explain the pathophysiological mechanism of DCI and, possibly, other clinical entities associated with *livedo reticularis*. Besides this, it is likely that *cutis marmorata* may have multiple causes, including local or systemic effects of bubbles.

The presence of *cutis marmorata* may be a prelude to a more serious clinical DCI syndrome and requires immediate appropriate treatment. These findings also suggest that the classification system traditionally used is insufficient and, therefore, we prefer to use the more inclusive term 'decompression illness' which has largely replaced the earlier three-tiered classification system.¹

Conclusion

Based on this case report, the findings from our pig CAGE studies and additional literature, we hypothesise that *cutis marmorata* in DCI may be caused by the presence of an intracranial air embolism, most likely associated with the presence of a right-to-left shunt, resulting in an AGE. Although the exact mechanism remains unclear, we postulate that bubbles or bubble-related effects in the

brain arteries give rise to the release of neuropeptides and, in turn, cause an inflammatory response. This hypothesis may be supported by the fact that *cutis marmorata* is also found in other non-diving fields of medicine in which intracranial pathology is present, with or without coagulation abnormalities. A weakness of our animal studies is the lack of immunocytochemical information. Additional research in which such measurements are performed may provide additional evidence to support this hypothesis and further explain the pathophysiological mechanism of DCI and, possibly, other clinical entities associated with *livedo reticularis*.

References

- 1 Vann RD, Butler FK, Mitchell SJ, Moon RE. Decompression illness. *Lancet*. 2011;377:153-64.
- 2 Tasios K, Sidirias GG, Kalentzos V, Pырpasopoulou A. Cutaneous decompression sickness. *Diving Hyperb Med*. 2014;44:45-7.
- 3 Erasmus DB, Alvarez F, Keller CA. Fatal arterial gas embolism in an adult 1 year after bilateral sequential lung transplantation. *J Heart Lung Transplant*. 2008;27:692-4.
- 4 Zaugg M, Kaplan V, Widmer U, Baumann PC, Russi EW. Fatal air embolism in an airplane passenger with a giant intrapulmonary bronchogenic cyst. *Am J Respir Crit Care Med*. 1998;157:1686-9.
- 5 Weenink RP, Hollmann MW, van Hulst RA. Acute neurological symptoms during hypobaric exposure: consider cerebral air embolism. *Aviat Space Environ Med*. 2012;83:1084-91.
- 6 Wilmshurst PT, Pearson MJ, Walsh KP, Morrison WL, Bryson P. Relationship between right-to-left shunts and cutaneous decompression illness. *Clin Sci*. 2001;100:539-42.
- 7 van Hulst RA, Lameris TW, Hasan D, Klein J, Lachmann B. Effects of cerebral air embolism on brain metabolism in pigs. *Acta Neurol Scand*. 2003;108:118-24.
- 8 Weenink RP, Hollmann MW, Vrijdag XC, Van Lienden KP, De Boo DW, Stevens MF, et al. Hyperbaric oxygen does not improve cerebral function when started 2 or 4 hours after cerebral arterial gas embolism in swine. *Crit Care Med*. 2013; 41: 1719-27.
- 9 Modell MM: Cutis marmorata marbling in an individual with decompression illness following repetitive SCUBA diving. *BMJ Case Rep*. 2014;doi:10.1136/bcr-2014-203975.
- 10 Oode Y, Yanagawa Y, Inoue T, Oomori K, Osaka H, Okamoto K. Cutaneous manifestation of decompression sickness: cutis marmorata. *Intern Med*. 2013;52:2479.
- 11 Luger TA: Neuromediators – a crucial component of the skin immune system. *J Dermatol Sci*. 2002;30:87-93.
- 12 Bianchi B, Katsambas A, Lotti TM. Neuropeptides and endothelial injury in cutaneous vasculitis. *Clin Dermatol*. 1999;17:625-7.
- 13 Buttolph TB, Dick EJ jr, Toner CB, Broome JR, Williams R, Kang YH, Wilt NL. Cutaneous lesions in swine after decompression: histopathology and ultrastructure. *Undersea Hyperb Med*. 1998;25:115-21.
- 14 Kalentzos VN. Cutis marmorata in decompression sickness. *New Engl J Med*. 2010, doi:10.1056/nejmicm0909444.
- 15 Kraemer M, Linden D, Berlit P. The spectrum of differential diagnosis in neurological patients with livedo reticularis and livedo racemosa: a literature review. *J Neurol*. 2005;252:1155-66.
- 16 Uhtman IW, Khamashta MA. Livedo racemosa: a striking

dermatological sign for the antiphospholipid syndrome. *J Rheumatol.* 2006;33-12:2379-82.

- 17 Wu S, Xu Z, Liang H. Sneddon's syndrome: a comprehensive review of the literature. *Orphanet J Rare Dis.* 2014;9:215 doi:10.1186/s13023-014-0215-4.
- 18 Richards KA, Paller AS. Livedo Reticularis in a Child with Moyamoya Disease. *Pediatr Dermatol.* 2003;20-2:124-7.

Acknowledgements

We thank the patient for permission to publish her clinical details. Grant approvals for animal studies include: DAA 100909, 27-09-2007 and Grant 009-07-5041-01, Ministry of Defence, 27-01-2009.

Conflicts of interest: nil

Submitted: 05 September 2014; revised 03 March 2015

Accepted: 04 April 2015

Tom CPM Kemper^{1,4}, R Rienks², PJAM van Ooij³, RA van Hulst⁴
¹Department of Cardiothoracic Surgery, Onze Lieve Vrouwe Gasthuis, Amsterdam, The Netherlands

²Department of Cardiology, Central Military Hospital, Utrecht, The Netherlands

³Diving Medical Center, Royal Netherlands Navy, Den Helder, The Netherlands

⁴Department of Anesthesiology/Hyperbaric Medicine, Academic Medical Center, Amsterdam, The Netherlands

Address for correspondence:

TCPM Kemper

Department of Cardiothoracic Surgery

Onze Lieve Vrouwe Gasthuis,

Amsterdam, Oosterpark 9

1091 AC Amsterdam, The Netherlands

Phone: +31-(0)6-5799-3488

E-mail: <t.kemper@me.com>

DIVE SMART DIVE SECURE

Be a DAN Member

- Worldwide Emergency Evacuation • 24/7 Medical Assistance
- Subscription to 'Alert Diver' DAN's Dive Health & Safety Magazine
- Travel Assistance Benefits (Travel, Personal, Legal, Medical)
- Dive Injury (Treatment) Insurance • DAN Product Discounts

To Find Out More or to Become a DAN Member ...

Nationals/Residents of the Asia-Pacific visit www.danasiapacific.org

European Nationals/Residents visit www.daneurope.org



A lot of protection at a very small cost!