

# An insight to tympanic membrane perforation pressure through morphometry: A cadaver study

Derya Ümit Talas<sup>1</sup>, Orhan Beger<sup>2</sup>, Ülkü Çömelekoğlu<sup>3</sup>, Salim Çakır<sup>4</sup>, Pourya Taghipour<sup>4</sup>, Yusuf Vayisoğlu<sup>1</sup>

<sup>1</sup> Mersin University Faculty of Medicine, Department of Otorhinolaryngology, Mersin, Turkey

<sup>2</sup> Mersin University Faculty of Medicine, Department of Anatomy, Mersin, Turkey

<sup>3</sup> Mersin University Faculty of Medicine, Department of Biophysics, Mersin, Turkey

<sup>4</sup> Mersin University Faculty of Medicine, Mersin, Turkey

**Corresponding author:** Orhan Beger, Mersin University Faculty of Medicine, Department of Anatomy, Ciftlikkoy Campus, 33343, Mersin, Turkey

[obeger@gmail.com](mailto:obeger@gmail.com)

## Key words

Bursting pressure, Cadaver, Ear barotrauma; Eardrum; Diving; Transducer

## Abstract

(Talas DÜ, Beger O, Çömelekoğlu Ü, Çakır S, Taghipour P, Vayisoğlu Y. An insight to tympanic membrane perforation pressure through morphometry: A cadaver study. *Diving and Hyperbaric Medicine*. 2021 March 31;51(1):10–17. [doi: 10.28920/dhm51.1.10-17](https://doi.org/10.28920/dhm51.1.10-17). PMID: 33761536.)

**Introduction:** A cadaveric experimental investigation aimed to show the rupture pressure of the tympanic membrane (TM) for otologists to evaluate its tensile strength.

**Methods:** Twenty adult ears in 10 fresh frozen whole cadaveric heads (four males, six females) mean age 72.8 (SD 13.8) years (range 40–86) were studied. The tensile strength of the TM was evaluated with bursting pressure of the membrane. The dimensions of the membranes and perforations were measured with digital imaging software.

**Results:** The mean bursting pressure of the TM was 97.71 (SD 36.20) kPa. The mean area, vertical and horizontal diameters of the TM were 57.46 (16.23) mm<sup>2</sup>, 9.54 (1.27) mm, 7.99 (1.08) mm respectively. The mean area, length and width of the perforations were 0.55 (0.25) mm<sup>2</sup>, 1.37 (0.50) mm, and 0.52 (0.22) mm, respectively. Comparisons of TM dimension, bursting pressure, and perforation size by laterality and gender showed no significant differences. The bursting pressure did not correlate (positively or negatively) with the TM or perforation sizes.

**Conclusions:** The TM can rupture during activities such as freediving or scuba diving, potentially leading to serious problems including brain injuries. Studying such events via cadaveric studies and data from case studies is of fundamental importance. The minimum experimental bursting pressures might better be taken into consideration rather than average values as the danger threshold for prevention of TM damage (and complications thereof) by barotrauma.

## Introduction

The tympanic membrane (TM), a thin, oval-shaped, semi-transparent drum, transmits sound waves from the external auditory canal (EAC) to the ear ossicles, and then to the cochlea.<sup>1</sup> The shape, elasticity and size of the TM are influential on its function.<sup>2</sup> Hearing loss due to perforation or rupture can occur when the TM is exposed to air or water pressures that exceed its mechanical capacity.<sup>3–8</sup> Perforations depend on environmental conditions in addition to the intrinsic properties of the membrane.<sup>6</sup> For instance, air pressure at 20,000 m altitude (5.47 kPa) is approximately 5.4% of sea level (101.32 kPa).<sup>6</sup> Moreover, in seawater, ambient pressure increases by 101.3 kPa (i.e., 760 mmHg or 1 atmosphere) every 10 m depth.<sup>6</sup> A TM rupture may occur due to pressure changes during diving, scuba diving, freediving, slap in face, martial arts, air travel, and blast injury.<sup>9–13</sup> These conditions causing overpressure (e.g., scuba diving or freediving) can lead to symptoms such as otalgia, vertigo, and hearing loss if appropriate equipment

(maybe special equipment for individuals with scarred TM) is not used.<sup>7,9,11</sup> Knowledge of the perforation threshold of the TM could contribute to the adaptation of devices used during sports activities (e.g., diving or martial arts), and to the development of protective military equipment (e.g., against combat explosions).<sup>7,8,10,11,13</sup> There is currently insufficient data regarding the bursting pressure of the TM in humans.<sup>7,8,14</sup>

TM rupture may be repaired with paper patches, cartilage, deep temporalis fascia, dura, or fat during myringoplasty or tympanoplasty.<sup>4,5,9,15,16</sup> The perforation dimension and in the diameters of the TM are important for ear surgeons in terms of preoperative choice of graft sizes.<sup>15</sup> The classic textbook reports that TM diameters lie in a narrow range (9–10 mm height, and 8–9 mm width);<sup>1</sup> however, some ear specialists have observed that the TM sizes vary widely among individuals (5 mm for the horizontal diameter).<sup>5</sup> New studies focusing on the dimensions of the TM can help ear surgeons estimate its size. In previous studies,<sup>6–8</sup> the

location of perforations has been evaluated after exposure to bursting pressure; however, it seems that variation of perforation dimensions in relation to the pressure exposure has been ignored. Furthermore, the relationship between TM diameters and bursting pressure could be useful for understanding the effect of dimension on its mechanical capacity. This study aimed to measure perforation pressure of the TM to provide a better understanding of its tensile strength, and to measure perforation size in terms of preoperative graft design.

## Methods

The study was approved by the ethical board of the Mersin University Faculty of Medicine.

### PREPARATION OF THE EARS

Twenty ears in 10 fresh frozen cadaver heads (4 males, 6 females) mean age 72.8 (SD 13.8) years (range 40–86 years) were included in the study. The heads were positioned in accordance with otologic surgery, and then the senior otologist (DÜT) cleared the EAC under a surgical microscope (Carl Zeiss f170, Carl Zeiss Meditec AG, Germany). Photographs of the TMs were taken before and after exposure to perforation pressure.

### MEASUREMENT OF TM PERFORATION PRESSURE


Two plastic tubes were placed inside a rubber ear plug. The proximal end of one of the tubes was connected to an air-filled syringe (20 cc), while the other proximal end was connected to a pressure transducer. The ear plug and the distal ends of the tubes were tightly bonded with glue to prevent air leaks. After the plug was placed in the ear, the air in the syringe was delivered to the EAC by the same researcher (OB). Pressure data were collected by an electrophysiological recording acquisition system (BIOPAC MP 100, Systems Inc., Santa Barbara, CA, USA) and then transferred to a computer via a 16 bit analog to digital converter for off line analysis (Figure 1). The sampling rate was 200-sec<sup>-1</sup>. BIOPAC Acknowledge Analysis Software (ACK 100 W) was used to evaluate the pressure data. The highest pressure before a sudden brief downward deflection in the graphs was recorded as the perforation pressure of the TM (Figure 2 arrow).

### MEASUREMENTS OF THE TM AND PERFORATION SIZES

Using a 0°, 4 mm diameter, 18 cm length endoscope (Karl Storz GmbH & Co., Tuttlingen, Germany), photographs of the TM were taken using a SPIES H3-Z three-chip full HD camera connected to a monitor (Karl Storz GmbH., Tuttlingen, Germany) with a millimeter scale. To determine the TM size including its surface area, height and width, the photos were transferred to digital image analysis software (Rasband WS, ImageJ, US National Institutes of Health,

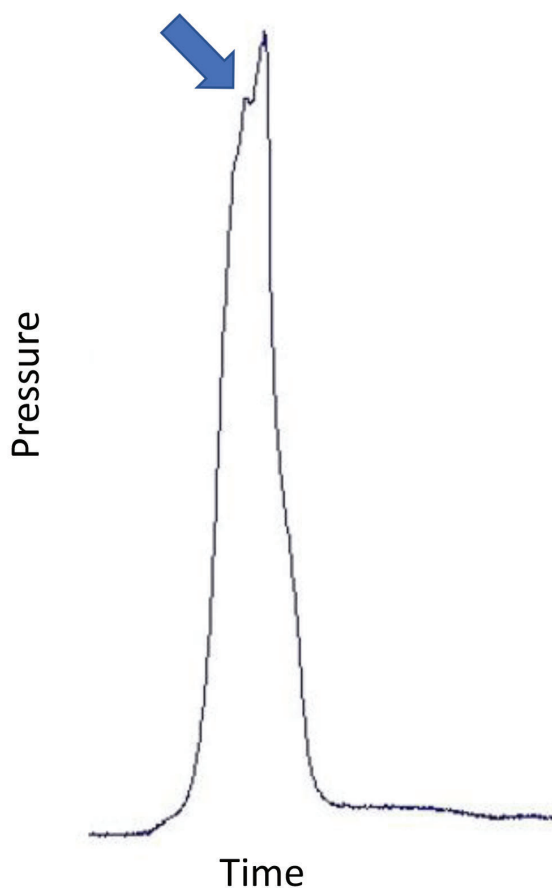
**Figure 1**

Experimental set-up showing syringe and transducer configuration, monitoring, and preparation of the cadaver ear



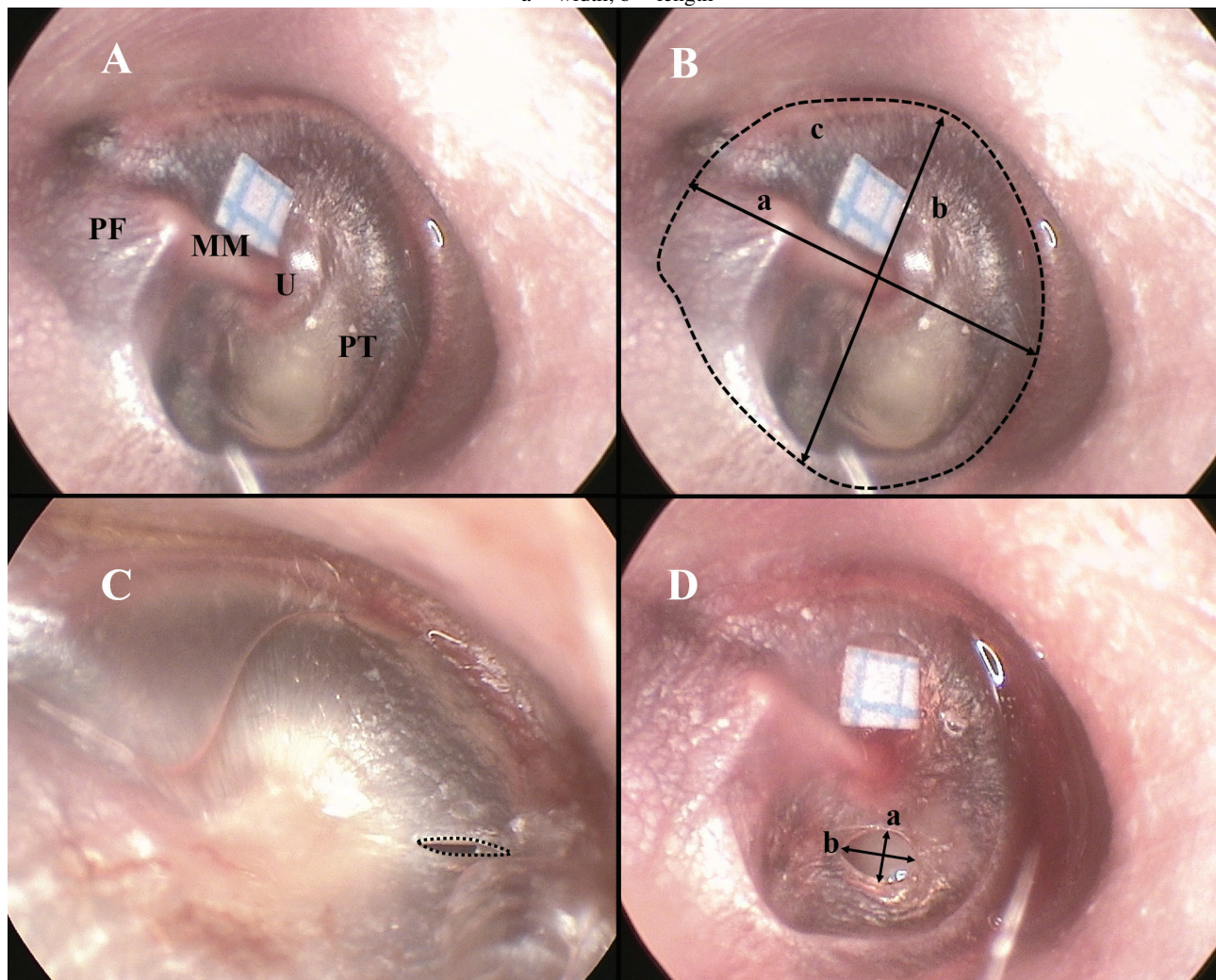
**Figure 2**

Representative pressure chart during a perforation pressure experiment showing the characteristic notch at the point of perforation (arrow)



**Figure 3**

A: Typical tympanic membrane. MM – manubrium mallei; U – umbo; PT – pars tensa; PF – pars flaccida. B: Tympanic membrane measurements. a – vertical diameter; b – horizontal diameter; c – the surface area. C: Perforation area. D: Perforation dimensions. a – width; b – length



Bethesda, Maryland, USA). After the pressure exposure, the TM was re-photographed to determine the location of the perforation, and to measure the perforation length, width and area. Measured parameters related to the TM and perforation (Figure 3) were: the surface area of the TM (TMA); the vertical diameter of the TM (the line passing through the manubrium mallei) (TMVD); the horizontal diameter of the TM (the line passing through the umbo perpendicular to the handle of malleus) (TMHD); the length of the perforation (at the longest level) (PL); the width of the perforation (at the widest level) (PW); the surface area of the perforation (PA).

#### STATISTICAL ANALYSIS

Normality checks of the dataset including dimensional and pressure measurements were performed with the Shapiro-Wilk test. Student's *t*-tests were used to compare TMVD – TMHD (paired sample *t*-test), male – female (independent sample *t*-test), and right – left sides (paired sample *t*-test).

Correlations between the parameters including dimension and pressure measurements of the TM were evaluated with the Pearson correlation coefficient test. A *P*-value < 0.05 was considered statistically significant.

#### Results

Data were normally distributed and therefore data were presented as mean and standard deviation (SD).

The mean perforation pressure for all ears was 97.71 (SD 36.20) kPa, range 35.79–151.78. In terms of sexes or sides, the TM size (length, width and area), perforation pressure, and perforation size (length, width and area) did not show statistically significant differences (Table 1).

The TMVD - TMHD ( $P < 0.001$ ,  $r = 0.710$ ), the TMVD - TMA ( $P < 0.001$ ,  $r = 0.870$ ), and the TMHD - TMA ( $P = 0.001$ ,  $r = 0.788$ ) showed strong positive correlations

**Table 1**

Perforation pressure and TM dimensional data. Data are mean (SD) [range]. PA – perforation area; PL – perforation length; PP – perforation pressure; PW – perforation width; TMA – tympanic membrane area; TMHD – tympanic membrane horizontal diameter; TMVD – tympanic membrane vertical diameter

Parameter	All ears	Right	Left	P	Female	Male	P
PP (kPa)	97.71 (36.20) [35.79–151.78]	96.86 (33.72)	98.57 (40.35)	0.92	100.22 (38.30)	93.95 (35.00)	0.72
TMVD (mm)	9.54 (1.27) [7.23–11.61]	9.99 (1.15)	9.09 (1.28)	0.12	9.64 (1.37)	9.38 (1.18)	0.67
TMHD (mm)	7.99 (1.08) [5.85–9.74]	8.26 (1.20)	7.73 (0.94)	0.28	7.89 (1.12)	8.15 (1.08)	0.62
TMA (mm <sup>2</sup> )	57.46 (16.23) [33.45–93.43]	62.03 (16.16)	52.89 (15.88)	0.22	58.16 (17.72)	56.41 (14.84)	0.82
PL (mm)	1.37 (0.50) [0.51–2.51]	1.42 (0.42)	1.32 (0.59)	0.67	1.35 (0.56)	1.40 (0.43)	0.82
PW (mm)	0.52 (0.22) [0.22–1.04]	0.61 (0.25)	0.42 (0.12)	0.06	0.55 (0.23)	0.46 (0.20)	0.40
PA (mm <sup>2</sup> )	0.55 (0.25) [0.19–1.20]	0.59 (0.30)	0.50 (0.19)	0.45	0.52 (0.28)	0.59 (0.18)	0.59

**Table 2**

Correlation coefficients and P-values between parameters related to the TM. Bold and italic are statistically significant correlations. PA – perforation area; PL – perforation length; PP – perforation pressure; PW – perforation width; TMA – tympanic membrane area; TMHD – tympanic membrane horizontal diameter; TMVD – tympanic membrane vertical diameter

Parameter	TMVD	TMHD	TMA	PL	PW	PA
PP	-0.054 0.820	-0.194 0.412	-0.118 0.620	0.022 0.926	-0.249 0.290	-0.096 0.688
TMVD		<b><i>0.710</i></b> <b><i>&lt; 0.001</i></b>	<b><i>0.870</i></b> <b><i>&lt; 0.001</i></b>	-0.439 0.053	-0.093 0.698	<b><i>-0.493</i></b> <b><i>0.027</i></b>
TMHD			<b><i>0.788</i></b> <b><i>&lt; 0.001</i></b>	-0.133 0.576	0.010 0.967	-0.288 0.218
TMA				-0.228 0.334	-0.168 0.479	<b><i>-0.544</i></b> <b><i>0.013</i></b>
PL					0.122 0.608	<b><i>0.452</i></b> <b><i>0.045</i></b>
PW						0.527 0.017

(Table 2). The PL - PA ( $P = 0.045$ ,  $r = 0.452$ ) and the PW - PA ( $P = 0.017$ ,  $r = 0.527$ ) showed weak positive correlations (Table 2). The TMVD - PA ( $P = 0.027$ ,  $r = 0.493$ ) and the TMA - PA ( $P = 0.013$ ,  $r = 0.544$ ) showed weak negative correlations (Table 2).

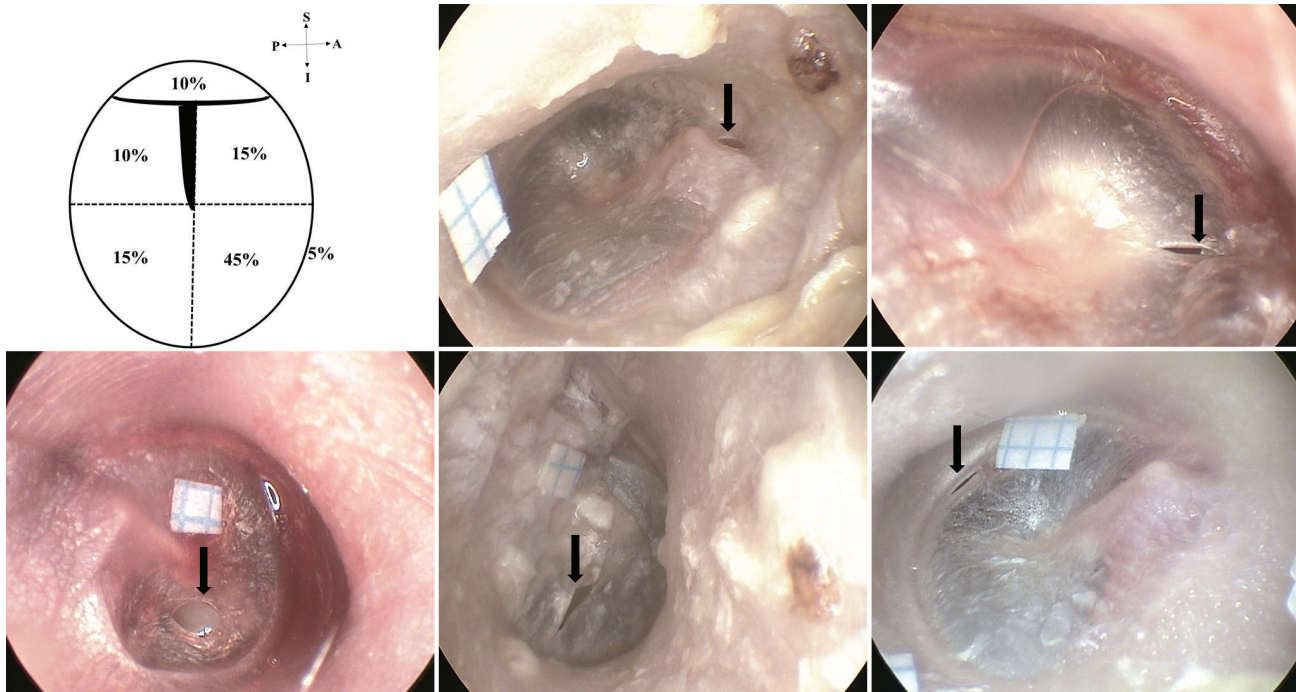
Two of 20 ruptures occurred in the pars flaccida, nine in the anterior-inferior quadrant, three in the anterior-superior quadrant, three in the posterior-inferior quadrant, and two in the posterior-superior quadrant. There was just one marginal perforation (Figure 4).

**Discussion**

Barotrauma caused by scuba diving, freediving, a slap to the face, martial arts, air travel, and blast injury can occur in the middle or inner ear.<sup>3,5,9-13</sup> When the pressure rises above the hazardous level for the middle ear, the Eustachian tube fails to balance the pressure.<sup>6,7</sup> Rupture of the TM is one of the important indicators that the dangerous level has been exceeded.<sup>6-8,14,17,18</sup> The average overpressure value for perforation of the TM in one study was 171.99 kPa (1,290 mmHg).<sup>8</sup> Others observed that this pressure level could be reached at 17.6 metres' sea water (msw).<sup>6</sup> In

**Figure 4**

Schematic TM and percentages of perforations (upper left panel). Two perforations (10%) in the pars flaccida (upper middle photo), nine (45%) in the anterior-inferior quadrant (upper right photo), three (15%) in the posterior-inferior quadrants (lower left photo), two (10%) in the posterior-superior quadrant (lower middle photo), one (5%) marginal perforation (lower right photo)



addition, it was suggested that epidural tears at pressures above this level (pressures between 171.99–246.65 kPa, i.e., 1290–1850 mmHg; depths between 17.6–25.2 msw) might be seen.<sup>6</sup> In a scuba diver who descended 9.14 msw (92.03 kPa) and developed otalgia, vertigo and hearing loss, computed tomography showed haemorrhage in the temporal lobe due to barotrauma causing the rupture of the tegmen tympani (gas in the middle cranial fossa).<sup>19</sup> In this regard, knowledge of the perforation pressure threshold of the TM may be useful for otologists to evaluate possible pathological lesions located at the brain or temporal bone. The vast majority of information on perforation pressure in the literature was obtained from animal models.<sup>6,17,18,20,21</sup> However, those studies focused on different animals (e.g., rabbit, dogs, cattle, foxes, cats, or guinea pigs) and indicated that the perforation pressure of the TM in humans was greater than that in other species.<sup>6,17,18,20,21</sup> Considering that the data focusing on humans were limited and contradictory,<sup>7,8,14</sup> the present study aimed to further investigate perforation pressure of the TM in humans to better define the tensile strength of the membrane.

Pre-existing data related to perforation pressure of the TM in human cadaveric models are given in Table 3. The mean perforation pressure (97.71 (SD 36.20) kPa, range 35.79–151.78 kPa) in the present study was lower than those (means 117.68–172.37 kPa, range 40.53–303.97 kPa) reported in previous articles<sup>7,8,14</sup> that used similar methodology. However, the present study mean perforation pressure was higher than those studies which

tested the effect of blast overpressure (i.e., sound wave) (21–62.1 kPa).<sup>22,23</sup> The present perforation pressure was also higher than reported to be provoked by ear irrigation with water (32 kPa, range: 26.66–40 kPa).<sup>24</sup> Proposed reasons for differences in human TM perforation pressures include: demographics (e.g., region, age); methodology (e.g., transducer or bicycle pump); anatomical variations (e.g., the size and shape of the TM, external ear canal, or pinna); and present or past pathological lesions (e.g., scarred TM or eustachian tube dysfunction).<sup>7,21</sup> Similar to the present work, one study reported that sex and side differences did not affect the bursting pressure of the TM.<sup>14</sup> Some authors have observed that the perforation pressure was higher in children and decreased with age.<sup>7,14</sup> The perforation pressure in a German study<sup>14</sup> (160.09 kPa) was higher than that in a Danish study<sup>7</sup> (117.68 kPa) raising the possibility of regional differences. The perforation pressure in the present study (syringe and transducer) was lower than studies using a bicycle pump<sup>7,14</sup> and sphygmomanometer;<sup>8</sup> thus the pressure generator and measurement device might account for differences between studies. Some authors<sup>7,14</sup> found that the bursting pressure of a scarred TM (29.42–78.45 kPa) was significantly lower than that of a normal TM (40.53–303.97 kPa). One group suggested that the scarred TM could rupture when descending to 3 msw (30.20 kPa).<sup>7</sup> Therefore, many factors potentially influence the perforation pressure of the TM. Given that the TM can rupture during many activities such as spearfishing, swimming, diving, freediving, or scuba diving, we believe that the minimum values of bursting pressures reported

**Table 3**

Studies reporting TM perforation pressures expressed both in kPa and seawater depth equivalent (standard deviation) [range]. CB – closed bulla; msw – metres’ sea water; OB – open bulla; PP – perforation pressure; PPMT – perforation pressure measurement technique; Sphygmo – sphygmomanometer

Study	Year	Region	n	Species	TM	PPMT	PP (kPa)	PP (msw)
14	1906	Germany	111	Humans	Normal	bicycle pump	160.09 [40.53–303.97]	15.90 [4.02–30.19]
			12	Humans	Atrophic	bicycle pump	51.68	5.13
			12	Humans	Scarred	bicycle pump	30.40	3.02
7	1993	Denmark	144	Humans	Normal	bicycle pump	117.68 [49.03–205.94]	11.67 [4.87–20.45]
			23	Humans	Scarred	bicycle pump	58.84 [29.42–78.45]	5.84 [2.92–7.79]
18	2003	Australia	9	Pigs	Normal	Pressure gauge	121.59 (30.40)	12.07 (3.02)
17	2000	Norway	26	Cattle	Normal	Pressure gauge	39.52 [17.23–82.68]	3.92 [1.71–8.21]
			5	Foxes	Normal	Pressure gauge	59.78 [52.18–72.35]	5.94 [5.18–7.18]
20	1942	USA	–	Cats	Normal	Manometer	11.15	1.11
6	1971	USA	9	Guinea pigs	TM+OB	Transducer	26.66 (4.80) [18.53–32.53]	2.65 (0.48) [1.84–3.23]
			9	Guinea pigs	TM+CB	Transducer	33.46 (5.47) [25.86–41.60]	3.32 (0.54) [2.57–4.13]
8	1958	USA	15	Humans	Normal	Sphygmo	172.37 [96.53–227.53]	17.12 [9.59–22.60]
22	2019	USA	16	Humans	Normal	Blast chamber	32 [21–61]	3.19 [2.08–6.06]
23	2018	USA	41	Humans	Normal	Test chamber	[52.40–62.10]	[5.20–6.17]
24	1995	Denmark	20	Humans	Normal	Transducer	32 [26.66–40.00]	3.18 [2.65–3.97]
Present study	2020	Turkey	20	Humans	Normal	Transducer	97.71 (36.20)	9.70 (3.59)

**Table 4**

Studies reporting TM dimensions. All studies used dissected cadaveric ears. TMA – the area of the TM; TMHD – the horizontal diameter of the TM; TMVD – the vertical diameter of the TM; y – years

Study	Year	Region	n	Age	TMVD (mm)	TMHD (mm)	TMA (mm <sup>2</sup> )
2	1991	Belgium	–	Adult	–	–	59.74–65.35
28	1960	Japan	25	Adult	7.50 (0.50)	7.90 (0.80)	55.40 (4.50)
29	1970	USA	20	Adult	9.00–10.20	8.50–9.00	–
30	1991	Italy	280	Adult	9.40 (1.50)	8.60 (0.90)	–
31	1987	Israel	28	Adult	8–9	9–10	–
32	1993	Australia	3	0–0.5 y	9.3 (0.3)	8.7 (0.6)	–
			4	2–4 y	9.1 (0.6)	9.0 (0.7)	–
			5	4–6 y	8.9 (0.4)	9.4 (0.2)	–
			3	6–8 y	9.5 (0.5)	9.0 (0.9)	–
			3	8–10 y	8.8 (0.3)	9.0 (0.9)	–
			2	10–14 y	8.8 (0.4)	9.5	–
			7	14–18 y	9.4 (0.3)	9.3 (0.6)	–
			3	> 18 y	9.0	9.3 (0.4)	–
Present study	2020	Turkey	20	Adult	9.54 (1.27)	7.99 (1.08)	57.46 (16.23)

in the experimental studies (35.79–96.53 kPa) should be taken instead of the average values (97.71–172.37 kPa) as the danger threshold for the membrane (taking into account studies using methodology similar to our study). In this way, possible middle/inner ear damage due to barotrauma with or without coexistent pathologies such as brain injury might be prevented.

Perforation of the pars flaccida was found in 2/20 of cases depending on the bursting pressure, while the pars tensa perforated in the other 18 cases (Figure 4). The present finding of perforation predominantly in the anterior quadrants (60%) was compatible with previous data (~63% in two studies).<sup>7,8</sup> These findings indicate that the posterior quadrants have more elastic fibers than the anterior quadrants.<sup>7</sup> In clinical studies, perforations are mostly found in the central or anterior-central part of the TM.<sup>25–27</sup> For example, one study<sup>26</sup> reported that the TM perforation rate was 2.8% in the attic region (i.e., pars flaccida), 38.2% in the central region, 7.4% in the marginal region, 32.3% in the anterior-central region, and 19.3% in the posterior-central region.<sup>26</sup> These clinical findings are therefore broadly compatible with experimental findings.

Studies reporting TM dimensions are summarised in Table 4,<sup>2,28–32</sup> The data are broadly confluent with the present study findings; 9.54 (SD 1.27) mm for the TMVD, 7.99 (1.08) mm for the TMHD, and 57.46 (16.23) mm<sup>2</sup> for the TMA. In Gray's Anatomy,<sup>1</sup> narrow ranges for TMVD (9–10 mm) and TMHD (8–9 mm) were cited while others have quoted different measurements (TMVD 10 mm and TMHD as 5 mm).<sup>5</sup> It has also been claimed that the TMHD (9–10 mm) was greater than the TMVD (8–9 mm).<sup>31</sup> However, the present study found that the TMHD was statistically smaller than the TMVD as reported by others.<sup>29,30,33</sup> It has been suggested that measurement variations between studies may be attributable to the methodology (e.g., in situ vs. ex situ measurement).<sup>28,30</sup> The present study showed that the measurement range was quite wide (7.23–11.61 mm for the TMVD, and 5.85–9.74 mm for the TMHD). This information may be beneficial for otologists during preoperative graft design. It is notable that Treacher Collins syndrome, congenital aural atresia, and congenital cholesteatoma may be associated with anomalies of the TM;<sup>34–38</sup> therefore, knowledge of TM size in normal ears may be useful for interpreting anatomical variations of the EAC and middle ear in patients with congenital anomalies.

## Conclusion

The TM can rupture during many activities such as spearfishing, freediving, and scuba diving. This may be complicated by more serious problems including brain injuries. The establishment of accurate estimates of perforation pressure through experimental studies, cadaveric studies and clinical cases is of fundamental importance. Minimum values of the experimental studies

(35.79–96.53 kPa) might better represent the danger threshold for the bursting pressure of the TM than average values (97.71–172.37 kPa) in the prevention of TM damage.

## References

- 1 Standring S, Borley NR, Collins P, Crossman AR, Gatzoulis MA, Healy JC, editors. Gray's anatomy: The anatomical basis of clinical practice, 40th ed. London: Elsevier; 2008.
- 2 Decraemer WF, Dirckx JJ, Funnell WR. Shape and derived geometrical parameters of the adult, human tympanic membrane measured with a phase-shift moiré interferometer. *Hear Res.* 1991;51:107–21. doi: [10.1016/0378-5955\(91\)90010-7](https://doi.org/10.1016/0378-5955(91)90010-7). PMID: 2013538.
- 3 Herkal K, Ramasamy K, Saxena SK, Ganesan S, Alexander A. Hearing loss in tympanic membrane perforations: An analytic study. *Int J Otorhinolaryngol Head Neck Surg.* 2018;4:1233–9. doi: [10.18203/issn.2454-5929.ijohns20183693](https://doi.org/10.18203/issn.2454-5929.ijohns20183693).
- 4 Park MK, Kim KH, Lee JD, Lee BD. Repair of large traumatic tympanic membrane perforation with a Steri-Strips patch. *Otolaryngol Head Neck Surg.* 2011;145:581–5. doi: [10.1177/0194599811409836](https://doi.org/10.1177/0194599811409836). PMID: 21593464.
- 5 Wahid FI, Nagra SR. Incidence and characteristics of traumatic tympanic membrane perforation. *Pak J Med Sci.* 2018;34:1099–103. doi: [10.12669/pjms.345.15300](https://doi.org/10.12669/pjms.345.15300). PMID: 30344557. PMCID: PMC6191782.
- 6 Goldstein AJ, Mundie JR. Rupture of the tympanic membrane followed by sudden death. *Arch Otolaryngol.* 1971;93:140–6. doi: [10.1001/archotol.1971.00770060226006](https://doi.org/10.1001/archotol.1971.00770060226006). PMID: 5543152.
- 7 Jensen JH, Bonding P. Experimental pressure induced rupture of the tympanic membrane in man. *Acta Otolaryngol.* 1993;113:62–7. doi: [10.3109/00016489309135768](https://doi.org/10.3109/00016489309135768). PMID: 8442424.
- 8 Keller AP Jr. A study of the relationship of air pressure to myringorupture. *Laryngoscope.* 1958;68:2015–29. doi: [10.1288/00005537-195812000-00002](https://doi.org/10.1288/00005537-195812000-00002). PMID: 13621666.
- 9 Carniol ET, Bresler A, Shaigany K, Svider P, Baredes S, Eloy JA, et al. Traumatic tympanic membrane perforations diagnosed in emergency departments. *JAMA Otolaryngol Head Neck Surg.* 2018;144:136–9. doi: [10.1001/jamaoto.2017.2550](https://doi.org/10.1001/jamaoto.2017.2550). PMID: 29270620. PMCID: PMC5839286.
- 10 Fields JD, McKeag DB, Turner JL. Traumatic tympanic membrane rupture in a mixed martial arts competition. *Curr Sports Med Rep.* 2008;7:10–1. doi: [10.1097/01.CSMR.0000308672.53182.3b](https://doi.org/10.1097/01.CSMR.0000308672.53182.3b). PMID: 18296937.
- 11 Green SM, Rothrock SG, Green EA. Tympanometric evaluation of middle ear barotrauma during recreational scuba diving. *Int J Sports Med.* 1993;14:411–5. doi: [10.1055/s-2007-1021201](https://doi.org/10.1055/s-2007-1021201). PMID: 8244609.
- 12 Mirza S, Richardson H. Otic barotrauma from air travel. *J Laryngol Otol.* 2005;119:366–70. doi: [10.1258/0022215053945723](https://doi.org/10.1258/0022215053945723). PMID: 15949100.
- 13 Ritenour AE, Wickley A, Ritenour JS, Kriete BR, Blackbourne LH, Holcomb JB, et al. Tympanic membrane perforation and hearing loss from blast overpressure in Operation Enduring Freedom and Operation Iraqi Freedom wounded. *J Trauma.* 2008;64:174–8. doi: [10.1097/TA.0b013e318160773e](https://doi.org/10.1097/TA.0b013e318160773e). PMID: 18376162.
- 14 Zalewski T. Experimentelle Untersuchungen tiber die Resistenzfahigkeit des Trommelfells. *Zeitschrift für Ohrenheilkunde.* 1906;52:109–29. German.
- 15 Chow LCK, Hui Y, Wei WI. Permeatal temporalis fascia

- graft harvesting for minimally invasive myringoplasty. *Laryngoscope*. 2004;114:386–8. doi: [10.1097/00005537-200402000-00040](https://doi.org/10.1097/00005537-200402000-00040). PMID: 14755225.
- 16 Palva T, Ramsay H. Myringoplasty and tympanoplasty-results related to training and experience. *Clin Otolaryngol Allied Sci*. 1995;20:329–35. doi: [10.1111/j.1365-2273.1995.tb00053.x](https://doi.org/10.1111/j.1365-2273.1995.tb00053.x). PMID: 8548965.
  - 17 Kringlebotn M. Rupture pressures of membranes in the ear. *Ann Otol Rhinol Laryngol*. 2000;109:940–4. doi: [10.1177/000348940010901007](https://doi.org/10.1177/000348940010901007). PMID: 11051434.
  - 18 Thamrin C, Eikelboom RH. Pressures of the porcine tympanic membrane. *Ann Otol Rhinol Laryngol*. 2003;112:554–7. doi: [10.1177/000348940311200613](https://doi.org/10.1177/000348940311200613). PMID: 12834126.
  - 19 Cortes MD, Longridge NS, Lepawsky M, Nugent RA. Barotrauma presenting as temporal lobe injury secondary to temporal bone rupture. *AJNR Am J Neuroradiol*. 2005;26:1218–9. PMID: 15891187.
  - 20 Wever EG, Bray CW, Lawrence M. The effects of pressure in the middle ear. *J Exp Psychol*. 1942;30:40–52. doi: [10.1037/h0061283](https://doi.org/10.1037/h0061283).
  - 21 Richmond DR, Yelverton JT, Fletcher ER, Phillips YY. Physical correlates of eardrum rupture. *Ann Otol Rhinol Laryngol Suppl*. 1989;140:35–41. doi: [10.1177/00034894890980s507](https://doi.org/10.1177/00034894890980s507). PMID: 2497697.
  - 22 Liang J, Smith KD, Gan RZ, Lu H. The effect of blast overpressure on the mechanical properties of the human tympanic membrane. *J Mech Behav Biomed Mater*. 2019;100:103368. doi: [10.1016/j.jmbbm.2019.07.026](https://doi.org/10.1016/j.jmbbm.2019.07.026). PMID: 31473437.
  - 23 Gan RZ. Biomechanical changes of tympanic membrane to blast waves. *Adv Exp Med Biol*. 2018;1097:321–34. doi: [10.1007/978-3-319-96445-4\\_17](https://doi.org/10.1007/978-3-319-96445-4_17). PMID: 30315553.
  - 24 Sørensen VZ, Bonding P. Can ear irrigation cause rupture of the normal tympanic membrane?: An experimental study in man. *J Laryngol Otol*. 1995;109:1036–40. doi: [10.1017/s0022215100131974](https://doi.org/10.1017/s0022215100131974). PMID: 8551115.
  - 25 Das A, Sen B, Ghosh D, Sengupta A. Myringoplasty: Impact of size and site of perforation on the success rate. *Indian J Otolaryngol Head Neck Surg*. 2015;67:185–9. doi: [10.1007/s12070-014-0810-7](https://doi.org/10.1007/s12070-014-0810-7). PMID: 26075176. PMCID: PMC4460101.
  - 26 Adegbiji WA, Olajide GT, Olajuyin OA, Olatoke F, Nwawolo CC. Pattern of tympanic membrane perforation in a tertiary hospital in Nigeria. *Niger J Clin Pract*. 2018;21:1044–9. doi: [10.4103/njcp.njcp\\_380\\_17](https://doi.org/10.4103/njcp.njcp_380_17). PMID: 30074009.
  - 27 Pannu KK, Chadha S, Kumar D, Preeti. Evaluation of hearing loss in tympanic membrane perforation. *Indian J Otolaryngol Head Neck Surg*. 2011;63:208–13. doi: [10.1007/s12070-011-0129-6](https://doi.org/10.1007/s12070-011-0129-6). PMID: 22754796. PMCID: PMC3138953.
  - 28 Kirikae I. The structure and function of the middle ear. Tokyo: University of Tokyo Press; 1960.
  - 29 Lim DJ. Human tympanic membrane. An ultrastructural observation. *Acta Otolaryngol*. 1970;70:176–86. doi: [10.3109/00016487009181875](https://doi.org/10.3109/00016487009181875). PMID: 5477148.
  - 30 Salvinelli F, Maurizi M, Calamita S, D'Alatri L, Capelli A, Carbone A. The external ear and the tympanic membrane. A three-dimensional study. *Scand Audiol*. 1991;20:253–6. doi: [10.3109/01050399109045972](https://doi.org/10.3109/01050399109045972). PMID: 1842299.
  - 31 Wajnberg J. The true shape of the tympanic membrane. *J Laryngol Otol*. 1987;101:538–41. doi: [10.1017/s0022215100102191](https://doi.org/10.1017/s0022215100102191). PMID: 3598352.
  - 32 Dahm MC, Shepherd RK, Clark GM. The postnatal growth of the temporal bone and its implications for cochlear implantation in children. *Acta Otolaryngol Suppl*. 1993;505:1–39. doi: [10.3109/00016489309128539](https://doi.org/10.3109/00016489309128539). PMID: 8379315.
  - 33 Bruzewicz S, Suder E. Prenatal growth of the human tympanic membrane. *Ann Anat*. 2004;186:271–6. doi: [10.1016/S0940-9602\(04\)80016-5](https://doi.org/10.1016/S0940-9602(04)80016-5). PMID: 15255304.
  - 34 Jahrsdoerfer RA, Aguilar EA, Yeakley JW, Cole RR. Treacher Collins syndrome: An otologic challenge. *Ann Otol Rhinol Laryngol*. 1989;98:807–12. doi: [10.1177/000348948909801011](https://doi.org/10.1177/000348948909801011). PMID: 2802464.
  - 35 Kalejaiye A, Giri N, Brewer CC, Zalewski CK, King KA, Adams CD, et al. Otologic manifestations of Fanconi anemia and other inherited bone marrow failure syndromes. *Pediatr Blood Cancer*. 2016;63:2139–45. doi: [10.1002/pbc.26155](https://doi.org/10.1002/pbc.26155). PMID: 27428025.
  - 36 Schuknecht HF. Congenital aural atresia. *Laryngoscope*. 1989;99:908–17. doi: [10.1288/00005537-198909000-00004](https://doi.org/10.1288/00005537-198909000-00004). PMID: 2770382.
  - 37 Yoshida T, Sone M, Mizuno T, Nakashima T. Intratympanic membrane congenital cholesteatoma. *Int J Pediatr Otorhinolaryngol*. 2009;73:1003–5. doi: [10.1016/j.ijporl.2009.03.005](https://doi.org/10.1016/j.ijporl.2009.03.005). PMID: 19375176.
  - 38 Zhao S, Han D, Wang D, Li J, Dai H, Yu Z. The formation of sinus in congenital stenosis of external auditory canal with cholesteatoma. *Acta Otolaryngol*. 2008;128:866–70. doi: [10.1080/00016480701784940](https://doi.org/10.1080/00016480701784940). PMID: 18607966.

**Conflicts of interest and funding:** nil

**Submitted:** 15 June 2020

**Accepted after revision:** 30 August 2020

**Copyright:** This article is the copyright of the authors who grant *Diving and Hyperbaric Medicine* a non-exclusive licence to publish the article in electronic and other forms.