

# Case report

## Two unusual presentations of probable decompression sickness after deep mixed-gas recreational diving

Andrew Fock and Ian Millar

### Key words

Case reports, decompression sickness, decompression illness, technical diving, risk factors

### Abstract

(Fock A, Millar I. Two unusual presentations of probable decompression sickness after deep mixed-gas recreational diving. *Diving and Hyperbaric Medicine*. 2008; 38: 40-2.)

We present two unusual presentations of decompression sickness manifesting at previous injury sites after deep mixed-gas recreational diving. While previous injury is often cited as a predisposing factor in decompression illness, formal case reports of this phenomenon are rare in the diving literature.

### Introduction

Deep mixed-gas technical diving has gained in popularity over the last 20 years. It has allowed divers to access many dive sites previously out of the reach of recreational diving. Expeditions to explore deep wrecks have been popularised over the last few years and often involve multi-day multiple dive profiles to depths greater than 70 metres' sea water (msw) on live-aboard dive vessels in remote locations. These dives are often conducted using closed-circuit rebreather apparatus (CCR) and helium-containing gas mixtures. Not surprisingly, the dives involve substantial decompression stress and are generally viewed as standing outside the established boundaries of the known decompression tables. We present two case reports with unusual manifestations of decompression sickness in otherwise well divers after a series of deep mixed-gas dives.

### Case 1

An otherwise well, 44-year-old male diver with some 20 years' diving experience, and on no medication, had a past history of a fractured right humerus 18 years previously, which had required open reduction and internal fixation after an atrophic non-union. The plate and screws remained *in situ*. The diver had had one previous episode of musculo-skeletal decompression sickness (DCS) involving pain-only symptoms in the other arm some six years previously. This had completely resolved with recompression.

The diver conducted a series of 18 dives over nine days to between 56 msw and 69 msw using a CCR. A trimix diluent consisting of 10% oxygen (O<sub>2</sub>) and 60% helium (residuum nitrogen) was used for all dives with the onboard computers adjusting the mix by adding O<sub>2</sub> to maintain a constant partial pressure of oxygen (PPO<sub>2</sub>) of 131 kPa. Decompression was controlled by on-board mixed-gas diving computers (VR3™ and VISION™). These utilise modified versions of the Buhlmann ZHL-16 decompression model. Two dives per


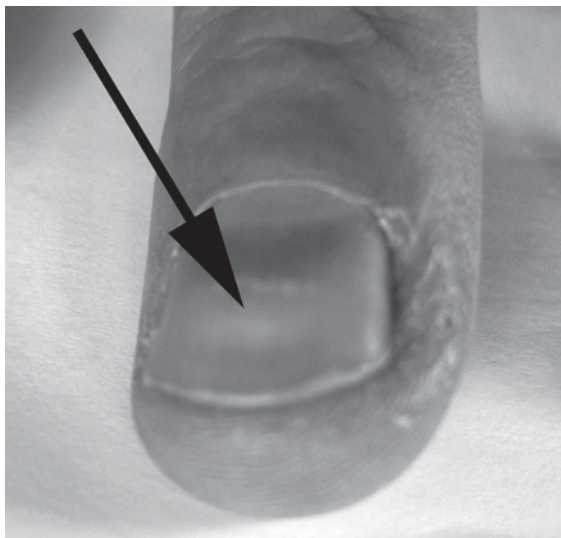
day were conducted with a surface interval of approximately four hours between dives. Bottom times were generally between 30 and 40 minutes' duration, with total dive times of approximately two hours. The diver increased his PPO<sub>2</sub> at the final stop to greater than 152 kPa by using surface-supplied O<sub>2</sub> or manually increasing the PPO<sub>2</sub> of the CCR unit.

After dive 15 of the series (67 msw for 35 minutes, total dive time (TDT) 1 hour 50 minutes) the diver experienced minor symptoms of DCS (equivocal pain in the right elbow) within a few minutes of surfacing. He immediately returned to 6 msw on the decompression station and remained there on 100% oxygen for 20 minutes. On return to the surface, all symptoms had resolved and did not subsequently return.

After dive 16 of the series (the second dive of the day, 68 msw, 31 minutes, TDT 149 minutes) the diver made an uneventful decompression, but on removing his wetsuit noticed palpable crepitus in the scar and over the plate in his right arm. This was confirmed by one of the authors (AF). The crepitus lasted for approximately 15 minutes before resolving spontaneously. The diver did not develop any further signs or symptoms of DCS; notably there was no rash associated with the area of crepitus or at any other site. Crepitus did not develop after dive 17 the following morning, but returned after dive 18 (68 msw, 31 minutes, TDT 2 hours 7 minutes) later that afternoon. Again, the crepitus resolved spontaneously over about 15 minutes. The diver did not develop any other symptoms of DCS and flew home 36 hours later without incident.

The diver was reviewed nine weeks later. In that time, the diver had developed transverse sulci consistent with Beau's lines across the thumb, index and ring fingernails of his right hand (Figure 1a and b). Close examination also revealed a slight sulcus across the nail of the left thumb, but no abnormalities of the nails of the other fingers or toes. The sulci on the affected fingers were located approximately 10 mm from the eponychium on each finger. The diver had been

**Figure 1**  
**Horizontal indentations (Beau's lines) in the nails of the fingers of the right hand of Case 1**



well in the intervening period and at no time had developed any symptoms consistent with decompression sickness.

**Case 2**

The diver was an otherwise well, 56-year-old male with more than 30 years' diving experience. He had an injury to his right eye as a child, complicated by acute glaucoma some years later and resulting in total blindness in that eye. The diver was using a CCR on the same expedition as Case one. However, due to marked hyperoxic-induced myopia, he generally limited himself to one long dive per day. PPO<sub>2</sub> was maintained at 141 kPa, and bottom times were usually of 40 to 60 minutes' duration, for total dive times of approximately three hours.

After dive 7 of the series, the diver returned to the surface after an uneventful decompression. Over the next 10 minutes or so he developed scintillating visual symptoms in the blind eye. He placed himself on 100% oxygen via his rebreather unit. After approximately 10 minutes the symptoms had resolved. No other neurological or systemic symptoms were noted. On close questioning, the diver revealed he had had similar episodes, usually after deep, long dives, which had also responded to oxygen. The diver continued to dive for the next two days without the reappearance of symptoms. He then had a two-day break before continuing on another similar diving expedition. Symptoms did not recur.

**Discussion**

Repetitive, deep, mixed-gas diving would be expected to produce considerable decompression stress. However, a previous study on a similar group of technical divers failed to show a significant increase in diver health status score.<sup>1</sup> During this most recent expedition, seven out of the eight divers developed marginal symptoms of DCS at one time or another during the expedition.<sup>1</sup> All cases responded

rapidly to either surface oxygen or immediate in-water recompression on 100% oxygen and no overt cases of DCS required formal recompression treatment.

Previous injury is often quoted as a predisposing factor for the development of DCS.<sup>2</sup> However, case reports are rare. Several skin manifestations are also described:<sup>3</sup>

- Pruritus with no rash
- Scarlatiniform rash with pruritus
- Erysipeloid rash
- Cutis marmorata
- Emphysema
- Lymphatic obstruction

Emphysema may be further divided into

- intracutaneous (minute blebs associated with mild pruritus reported in aviators only)
- subcutaneous emphysema associated with gas embolism.

In the first case, the subcutaneous emphysema observed did not conform to either of the above patterns. It was not associated with pruritus and was deeper than intracutaneous blebs. There was no obvious gas embolism. The location of the palpable gas over a potential nidus for bubble formation, in this case the stainless steel plate screwed to the humerus, or in the scar tissue from the previous surgery, suggests that the bubble formation may be a result of the reduced off-gassing due to alterations in local blood flow. An ultrasound to accurately locate the exact site of the bubbles would have been of great interest. It is conceivable that a build-up of tissue inert gas occurred in what is probably poorly perfused, damaged tissue over the course of the multiple daily exposures, with inadequate off-gassing occurring between dives despite no other overt symptoms developing in normally perfused tissues.

Beau's lines (transverse sulci of the nails) have been associated with a number of conditions (Table 1). They are

**Table 1**  
**Some conditions associated with Beau's lines<sup>4</sup>**

|   |
|---|
| Typhus  |
| Acute rheumatic fever                                   |
| Diphtheria  |
| Syphilis  |
| Malaria   |
| Vitamin deficiencies                                    |
| Myocardial infections                                   |
| Subacute and chronic pancreatitis<br>with malabsorption |
| Chemotherapy  |
| Acute gastrointestinal bleeding                         |
| Other severe metabolic stresses                         |

thought to represent a temporary arrest of the nail growth. They manifest as furrows in the nails that begin at the lunula and gradually move distally with growth. Fingernails grow at a rate of between 0.5 and 1.2 mm per week in a normal adult. The appearance of the Beau's lines in our case report, some 10 mm from the eponychium, would be consistent with the causative event occurring during the expedition.

Nail changes have been previously recorded in the diving literature. Schwartz reported changes similar to those that we observed in the nails of six divers during a helium-oxygen saturation dive to 1,100 feet of sea water (fsw) in 1986.<sup>4</sup> A similar dive to 1,000 fsw in 1988 also produced Beau's lines in a further two divers. Similar changes were noted by Hutchinson in a Mount Everest climber who spent six weeks at an altitude of above 5,500 m.<sup>5</sup> In all these cases, the lines were observed in the nails of all of the fingers. This is in contrast to our case, where the changes were restricted to three fingers of the right hand. It is interesting to speculate that the development of the Beau's lines may have been associated with the subcutaneous emphysema, which occurred some weeks earlier in the same arm during the diving expedition, and may represent more generalised bubble formation in peripheral sites. To the authors' knowledge, this is the first report of their occurrence after non-saturation decompression diving.

The second case presents more of a diagnostic dilemma. While the onset of the scintillating photopsia in his blind eye was temporally associated with his diving, such phenomena have also been associated with visual migraine. A recent Cochrane review has indicated that migraine is responsive to both hyperbaric and normobaric oxygen.<sup>6</sup> As this diver had had a prolonged exposure to 141 kPa of oxygen prior to the onset of symptoms, the diagnosis of migraine would be less likely. The diver does not normally suffer from migraine or photopsia, tending to implicate DCS as a more likely cause. The rapid response to surface oxygen might just as plausibly be expected from either migraine or DCS.

As with the first case, this diver continued to dive after symptoms were noted, without developing other symptoms of DCS (other than subjective worsening of his

hyperoxic-induced myopia). This would seem at odds with the commonly held belief that recent mild DCS predisposes to severe DCS if diving continues. In both cases, the subsequent dives were also in the 'extreme exposure' category according to dive tables. The lack of subsequent symptoms may be due in part to the high helium content of the diluent, allowing for continued off-gassing during the surface interval and the use of 100% or near 100% oxygen during the final phases of decompression. Whilst the authors would not encourage the practice of self treatment, continuation of diving after symptoms of DCS would seem to be common amongst technical divers. Anecdotally, this appears thus far to have produced few complications of a serious nature, at least in the divers with whom we have had contact.

### Conclusions

We present two unusual cases of probable DCS associated with previous injury, either resolving spontaneously or responding to normobaric O<sub>2</sub>. Neither case developed more classical symptoms of DCS despite ongoing diving to substantial depth using mixed gases.

### References

- 1 Fock AW. Health status and diving practices of a technical diving expedition. *Diving and Hyperbaric Medicine*. 2007; 36: 179-85.
- 2 Edmonds C, Lowry C, Pennefather J, Walker R. *Diving and subaquatic medicine*, 4th ed. London: Arnold; 2002.
- 3 Dennison WL. *A review of the pathogenesis of skin bends*. New London: NSMRL: US Navy Submarine Medical Centre Report No 660; 1971.
- 4 Schwartz H. Clinical observation: Beau's lines on fingernails after deep saturation dives. *Undersea Hyperb Med*. 2006; 33: 5-10.
- 5 Hutchison SJ, Amin S. Everest nails. *N Engl J Med*. 1997; 336: 229.
- 6 Bennett MH, French C, Kranke P, Schnabel A, Wasiak J. Normobaric and hyperbaric oxygen therapy for migraine and cluster headache. *Cochrane Database of Systematic Reviews*. 2005; Issue 2. Art. No.: CD005219. DOI: 10.1002/14651858.CD005219.

Submitted: 30 November 2008

Accepted: 07 January 2008

*Andrew Fock, MB, BS, FANZCA, Dip DHM, is a senior staff specialist and Ian Millar, MB, BS, FAFOM, Dip DHM, is the Medical Director in the Hyperbaric Services, The Alfred Hospital, Melbourne*

#### Address for correspondence:

*Dr Andrew Fock*

*The Alfred Hospital, Commercial Road, Prahran, Melbourne, Australia 3004*

**Phone:** +61-(0)3-9276-2269

**Fax:** +61-(0)3-9076-3052

**E-mail:** <a.fock@alfred.org.au>