

# Hyperbaric oxygen treatment and pulmonary air-containing lesions

Osman Türkmen<sup>1</sup>, Recep Özkan<sup>2</sup>, Kübra Özgök Kangal<sup>3</sup>, Merve Dur İnce<sup>4</sup>, Yakup Arslan<sup>5</sup>

<sup>1</sup> Department of Undersea and Hyperbaric Medicine, Samsun Training and Research Hospital, Samsun, Türkiye

<sup>2</sup> Department of Undersea and Hyperbaric Medicine, Van Training and Research Hospital, Van, Türkiye

<sup>3</sup> Department of Undersea and Hyperbaric Medicine, Health Sciences University, Gülhane Training and Research Hospital, Ankara, Türkiye

<sup>4</sup> Department of Radiology, Health Science University, Gülhane Training and Research Hospital, Ankara, Türkiye

<sup>5</sup> Department of Pulmonology, Health Sciences University, Gülhane Training and Research Hospital, Ankara, Türkiye

**Corresponding author:** Dr Osman Türkmen, Department of Undersea and Hyperbaric Medicine, Samsun Training and Research Hospital, Kadıköy Neighborhood, Barış Boulevard, No:199, 55090 İlkadım/Samsun, Türkiye

**ORCID:** [0000-0001-6819-4356](https://orcid.org/0000-0001-6819-4356)

[osman.turkmen@sbu.edu.tr](mailto:osman.turkmen@sbu.edu.tr)

## Keywords

Bullae; Lungs; Hyperbaric oxygen treatment; Pulmonary barotrauma

## Abstract

(Türkmen O, Özkan R, Özgök Kangal K, Dur İnce M, Arslan Y. Hyperbaric oxygen treatment and pulmonary air-containing lesions. *Diving and Hyperbaric Medicine*. 2025 December 20;55(4):343–351. doi: 10.28920/dhm55.4.343-351. PMID: 41364858.)

**Introduction:** Pulmonary barotrauma is a rare but serious complication of hyperbaric oxygen treatment. Pulmonary air-containing lesions may predispose pulmonary barotrauma by causing air trapping during changes in environmental pressure. This study aimed to investigate whether pulmonary air-containing lesions cause pulmonary barotrauma during hyperbaric oxygen treatment.

**Methods:** This study retrospectively analysed data from individuals who presented to the Undersea and Hyperbaric Medicine Clinic at Gülhane Training and Research Hospital, Health Sciences University, between 2017 and 2022. The relationship between presence of pulmonary air-containing lesions on computed tomography and pulmonary barotrauma was evaluated.

**Results:** Gas containing lesions were not associated with an increased risk of pulmonary barotrauma. The incidence of pneumothorax during hyperbaric oxygen was extremely low (0.0059% per session, 0.15% per patient).

**Conclusions:** Pulmonary air-containing lesions, including bullae, were not associated with an increased risk under standard hyperbaric oxygen treatment protocols. Routine chest computed tomography screening is not warranted due to the low complication rate. Nevertheless, clinical evaluation and informed consent are essential, particularly for patients with underlying lung disease. Further studies are needed to improve risk assessment.

## Introduction

Pressure and volume are inversely proportional according to Boyle's law. As the ambient pressure decreases, the volume of gas increases. Consequently, anatomical gas-containing spaces that do not freely equalise with ambient pressure may contract and expand during hyperbaric oxygen (HBO) treatment, depending on the phase of treatment (i.e., compression or decompression). Pulmonary overinflation can lead to disruption of the lung parenchyma, allowing air to enter the pulmonary interstitial spaces. Additionally, damage to the alveolar capillary vasculature may permit air to enter the bloodstream. This may manifest as local pulmonary injury, pneumomediastinum, subcutaneous emphysema, pneumothorax, or life-threatening arterial gas embolism.<sup>1</sup> Such pulmonary barotrauma (PBt) is a rare but serious complication of HBO treatment. Nevertheless, HBO treatment candidates should be screened for PBt risk factors, including chronic obstructive pulmonary disease (COPD), asthma, pulmonary blebs or bullae, and other pulmonary

lesions that could impair gas exchange. Screening involves medical history, physical examination, and pulmonary imaging if necessary. HBO treatment should be tailored on a case-by-case basis, considering the individual patient's risk factors.<sup>1</sup>

There are various lesions that may cause air trapping in the lungs. Pulmonary air-containing lesions (PACL) can appear in various forms in the lungs, including cysts, cavities, bullae, blebs, emphysema, pneumatocele, honeycombing and bronchiectasis.<sup>2,3</sup> In addition, the mosaic attenuation pattern, which may indicate obliterative small airways disease rather than a cystic pattern, should also be considered.<sup>2</sup> These pathologies may be a predisposing factor for PBt. In this respect, pre-HBO examination of respiratory system is an important step for hyperbaric physicians. Detailed respiratory medical history, auscultation and chest X-ray has been frequently used for respiratory system screening in patients/divers. In our department, we refer patients who have COPD, restrictive pulmonary disease or suspicious

air-trapping lesion on chest X-ray, to the pulmonology department for further evaluation. Informed consent is obtained from all patients scheduled to receive treatment.

The primary aim of our study was to evaluate whether PACL leads to PBt in HBO treatment. Additionally, we aimed to evaluate the incidence of PBt, determine the sensitivity and specificity of chest radiographs for pulmonary PACL, and examine the relationship between PBt and diseases affecting the lungs.

## Methods

The present study was approved by the Scientific Research Ethics Committee of Health Sciences University Gülhane Faculty of Medicine with project/decision number 2022-101, dated 17 March 2022. Additionally, the study was approved by the Scientific Research Platform of the Republic of Turkey Ministry of Health under application number 2022-01-18T14\_31\_33.

This study was carried out retrospectively at the Department of Undersea and Hyperbaric Medicine and The Department of Pulmonology in Gülhane Training and Research Hospital, Health Sciences University between 1 January 2017 and 31 December 2022. All patients screened before HBO treatment and who underwent HBO treatment in the Department of Undersea and Hyperbaric Medicine were included in this study. The inclusion criteria included having both chest X-ray and thoracic computed tomography (CT) images prior to HBO treatment. No chest CT scans were performed specifically for this study; instead, existing chest CT scans were reviewed.

We recorded age, gender, smoking history, smoking exposure (pack-years), smoking cessation history (years), history of lung disease, history of pneumothorax, chest X-ray findings, chest CT findings, symptoms and findings of PBt during HBO treatment, number of HBO sessions and need for mechanical ventilation during HBO sessions.

Chest X-ray and chest CT images were accessed via our hospital's picture archiving and communication systems. For patients with multiple chest CT scans, the scan closest to the date of admission was evaluated. Chest CT scans with artifacts or a slice thickness greater than 5 mm were excluded. To ensure that potential lesions were not overlooked, CT neck and CT abdomen scans containing lung sections, if available, were also evaluated.

The patients' chest X-ray images and chest CT scans were evaluated for PACL by author OT under the supervision of author YA (Pulmonology Specialist), and the radiology reports of the CT scans were reviewed. In addition, the CT scans of 100 randomly selected patients were independently evaluated for PACL by a blinded radiologist (author MD). Thus, two independent raters (OT/YA and MD) assessed the

presence or absence of PACL on CT scans, and inter-rater reliability was calculated to evaluate the consistency between their assessments.

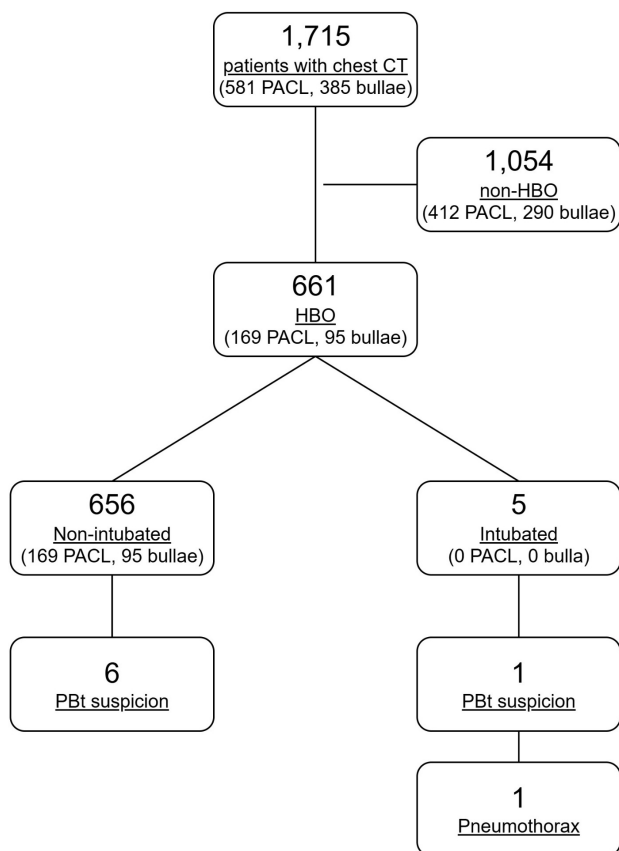
Different materials have characteristic and reproducible CT attenuation values, expressed in Hounsfield units (HU). CT scanners are calibrated to assign water an attenuation value of 0 HU. Materials with higher attenuation, such as soft tissue and bone, yield positive HU values, while materials with lower attenuation, such as air, correspond to negative HU values. Approximate HU values of different tissues on CT imaging are: -1,000 in air, -90 in fat, 0 in water, 30 in white matter, 40 in gray matter, 50 in muscle, and over 1,000 in cortical bone.<sup>4</sup> Normal lung tissue during inspiration exhibits relatively homogeneous low attenuation, with average HU values ranging from approximately -700 to -900.<sup>5</sup> Emphysema is characterised by low attenuation areas, defined using a HU threshold of -950.<sup>6</sup> In this study, for PACL, a threshold value of -950 Hounsfield units (HU) and below was considered for voxels. The type of PACL, their peripheral or central location, the affected lobe, and the maximum diameter of the largest lesion were recorded. Small pure hyperlucency areas were defined as PACL. Mosaic attenuation patterns were also documented. The locations of the lesions were categorised by lobes as the right upper, right middle, right lower, left upper, and left lower lobes.

The following symptoms and signs occurring during or after HBO were classified as PBt signs and symptoms: chest pain, cough, haemoptysis, substernal pressure, dyspnoea, tachypnoea, asymmetric breathing, and decreased breath sounds. The term 'PBt suspicion' refers to the physician's initial clinical assessment based on the patient's history, presenting symptoms, and physical examination findings. In most cases, the suspicion was based on respiratory symptoms, along with auscultation findings or other clinical clues. This term does not represent a confirmed diagnosis but rather reflects cases in which the physician considered the possibility of PBt.

The statistical analyses were performed using Jamovi version 2.3.28 (The Jamovi Project, Australia). Descriptive statistics derived from the study data included frequencies and percentages for categorical variables, while continuous variables were expressed as mean (standard deviation [SD]) for normally distributed data and as median with interquartile range (IQR) for non-normally distributed data. The normality of continuous variables was assessed with the Shapiro-Wilk test and histograms. For group comparisons, categorical variables were compared with Pearson's chi-square test or Fisher's exact test. The Mann-Whitney U test was used for non-normally distributed continuous variables. For normally distributed ordinal variables, homogeneity of variances was evaluated. If variances were homogeneous, the Student's *t*-test was used, while the Welch test was applied in cases of unequal variances. A *P*-value of < 0.05 was considered statistically significant.

**Figure 1**

Flowchart displaying patient selection and outcomes of investigation



**Results**

Between 1 January 2017, and 31 December 2022, a total of 1,715 individuals met the inclusion criteria. Of these, 661 (38.5%) received HBO treatment in our clinic. Among the remaining individuals, 29 (1.6%) were divers, six (0.3%) were inside tenders, and 1,019 (59.4%) did not receive HBO treatment in our clinic due to contraindications, refusal of treatment, or opting to begin treatment at another HBO centre. Although the original dataset consisted of two groups, the lesion characteristics of those who did not receive HBO treatment (non-HBO group) do not directly align with the core hypothesis or objectives of this study. Therefore, the analysis was focused solely on the group that received HBO treatment (HBO group). This approach was chosen to better understand the potential effects of HBO treatment on PACL and to make original contributions to the relevant literature. The non-HBO group was used solely to calculate the sensitivity of chest X-ray, to determine the etiology of PACL, and to estimate the prevalence of PACL. (Figure 1)

Only 238 (15.1%) of the chest CT scans were performed specifically for the HBO/diving examination. The remaining 1,477 scans (84.9%) were performed during follow-up evaluations in other departments (e.g., COPD screening in

**Table 1**

Descriptive statistical findings of the patients included in the study; COPD – chronic obstructive pulmonary disease; PACL – pulmonary air containing lesions; PTE – pulmonary thromboembolism

Parameter	Data
Age, median (IQR)	56 (26)
Sessions, median (IQR)	30 (15)
Intubated sessions, mean (SD)	4.8 (2.9)
<b>Sex</b>	
Male	526 (79.6)
Female	135 (20.4)
<b>Smoking</b>	
Smokers, <i>n</i> (%)	150 (22.7)
Non-smokers, <i>n</i> (%)	511 (77.3)
Current Smokers, <i>n</i> (%)	93 (62.0)
Pack years, median (IQR)	30 (23.8)
Quit Smoking, <i>n</i> (%)	57 (38)
Years since cessation, median (IQR)	14 (15.0)
<b>Comorbidities (n %)</b>	
Asthma	25 (3.8)
COPD	22 (3.3)
History of Covid19 pneumonia	10 (1.5)
Collagen Vascular disease	13 (2.0)
Buerger’s disease	10 (1.5)
History of pneumothorax	9 (1.4)
History of tuberculosis	6 (0.9)
History of PTE	4 (0.6)
Sarcoidosis	4 (0.6)
<b>PACL presence and location, <i>n</i> (%)</b>	
PACL present	169 (25.5)
PACL absent	492 (74.4)
Right upper lobe	84 (49.7)
Right Middle lobe	14 (8.2)
Right Lower lobe	25 (14.7)
Left Upper lobe	22 (13)
Left Lower lobe	23 (13.6)
Paratracheal	1 (0.5)
<b>PACL classification, <i>n</i> (%)</b>	
Bulla, bleb	95 (56.2)
Cyst, emphysema-like changes	56 (33.1)
Bronchiectasis	16 (9.4)
Cavity	1 (0.5)
Paratracheal diverticulum	1 (0.5)

the pulmonology department one year after HBO treatment, or for suspected pulmonary embolism in the emergency department six months prior to HBO treatment).

The median age of the HBO group was 56 years (IQR 26), and 79.6% of the patients were male (Table 1). A total of 16,710 HBO sessions were administered to 661 patients. Among these, 169 patients (25.6%) were diagnosed with PACL and collectively underwent 4,502 HBO treatment sessions. The chest CT sections of some of these patients are shown in Figure 2. Among the HBO group, five patients received a total of 24 sessions while intubated during treatment. Four of these patients were treated for anoxic brain injury and one for carbon monoxide poisoning. Mechanical ventilation was provided using the Draeger Oxylog 1000 (Drägerwerk, Germany) pneumatic ventilator.

Among these patients, the largest PACL diameter was eight cm (Figure 3). This patient had tuberculosis history and COPD diagnosis who completed 29 HBO treatment sessions without any complication. Chest X-ray before HBO treatment was evaluated and the patient was taken into treatment. The patient's bulla was detected on a chest CT scan performed by the pulmonology department one year after HBO treatment.

#### PATIENTS SUSPECTED OF PULMONARY BAROTRAUMA

Only seven of the 661 patients who received HBO treatment (Table 2) were evaluated for PBt due to the reported possible symptoms and findings. The symptoms were chest pain ( $n = 1$ , 14%), dyspnoea ( $n = 2$ , 28.5%), haemoptysis ( $n = 1$ , 14%), and low oxygen saturation observed at the end of HBO sessions. Regarding the findings, radiological

examinations revealed pneumothorax confirmed by chest radiograph in one patient, and localised pulmonary damage detected by high resolution CT (HRCT) in two patients. While pneumothorax is a definitive diagnostic finding, the parenchymal changes observed on CT are non-specific and were therefore categorised as possible PBt findings. The incidence of pneumothorax during HBO was 0.0059% per session and 0.15% per patient. No signs or symptoms consistent with arterial gas embolism were observed in any patients.

Patient 116 reported chest pain after the third session and was assessed with chest CT. This revealed localised pulmonary damage or consolidation in the left upper lobe, likely secondary to PBt (Figure 4). The patient subsequently continued HBO and completed treatment without complications. Pre-HBO spirometry and chest CT evaluations were normal.

Patient 306 reported haemoptysis after the 19th session and was referred to the Pulmonology Department. Chest CT revealed a lesion in the left upper lobe, suggesting localised pulmonary damage around emphysema-like changes (Figure 5). Previous spirometry had shown a restrictive pattern.

Patient 31 who had carbon monoxide intoxication required mechanical ventilation during HBO treatment. This patient developed hypoxaemia in the intensive care unit after the fourth HBO session. A right-sided pneumothorax was detected on the chest X-ray performed following the onset of hypoxaemia, and a chest tube was inserted. Due to the patient's unstable condition, HBO treatment was discontinued. Importantly, the chest CT performed prior to the initiation of HBO treatment was normal.

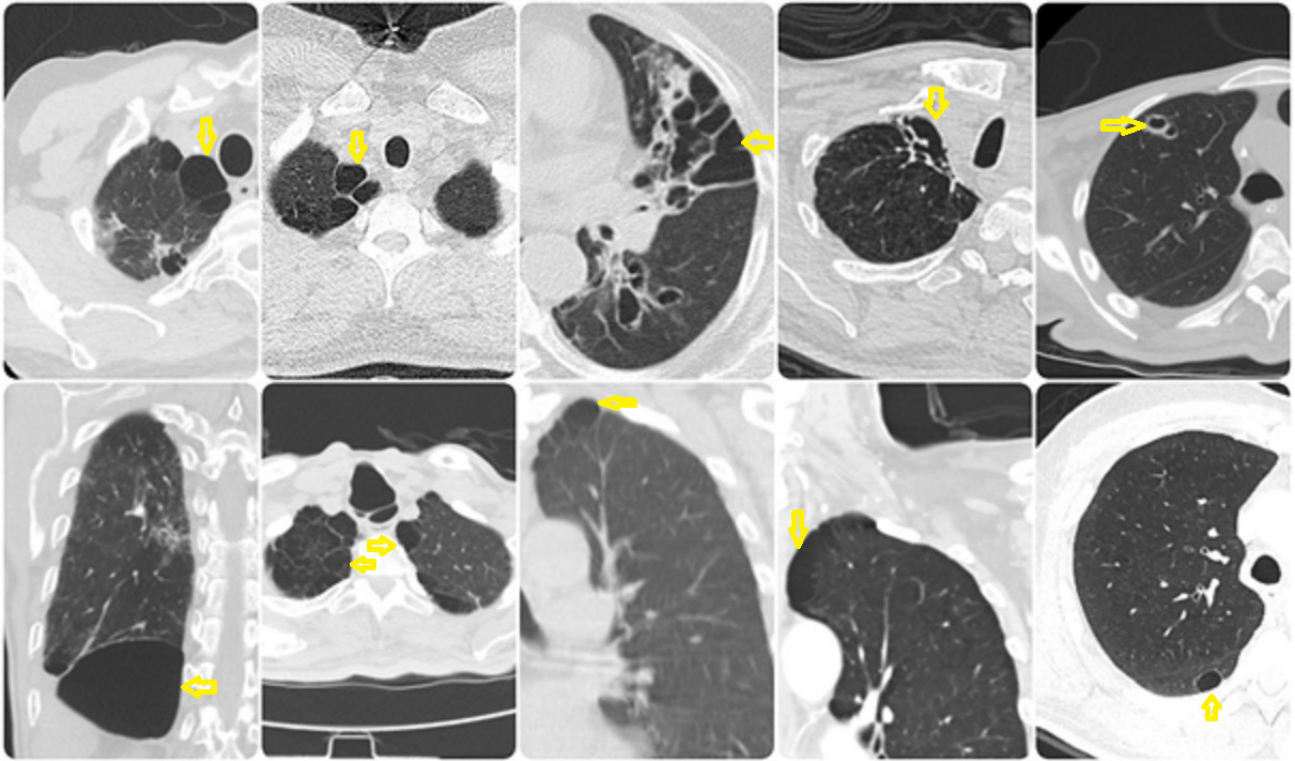
**Table 2**

List of patients suspected of pulmonary barotrauma; <sup>a</sup> linear opacity increase surrounding the emphysema-like changes in the left upper lobe (possible haemorrhage?); <sup>b</sup> consolidation in the posterior left upper lobe; CT – computed tomography; Echo – echocardiography; HRCT – high resolution computed tomography; PACL – pulmonary air containing lesions; PBt – pulmonary barotrauma

Patient	Comorbidity	Signs and symptoms	Evaluation of PBt	PBt evaluation result	Incidental PACL
6	–	Chest pain, dyspnoea	Chest radiograph	No pathological findings	Not detected
31	–	Desaturation	Chest radiograph	Pneumothorax	Not detected
116	–	Chest pain	HRCT	Localised pulmonary injury <sup>a</sup>	Not detected
306	Restrictive spirometry	Haemoptysis	HRCT	Localised pulmonary injury <sup>b</sup>	Detected
401	–	Chest pain, dyspnoea	Echo, CT angiography	No pathological findings	Not detected
476	–	Dyspnoea	Chest radiograph	No pathological findings	Not detected
613	Sarcoidosis	Dyspnoea	Physical examination	No pathological findings	Detected

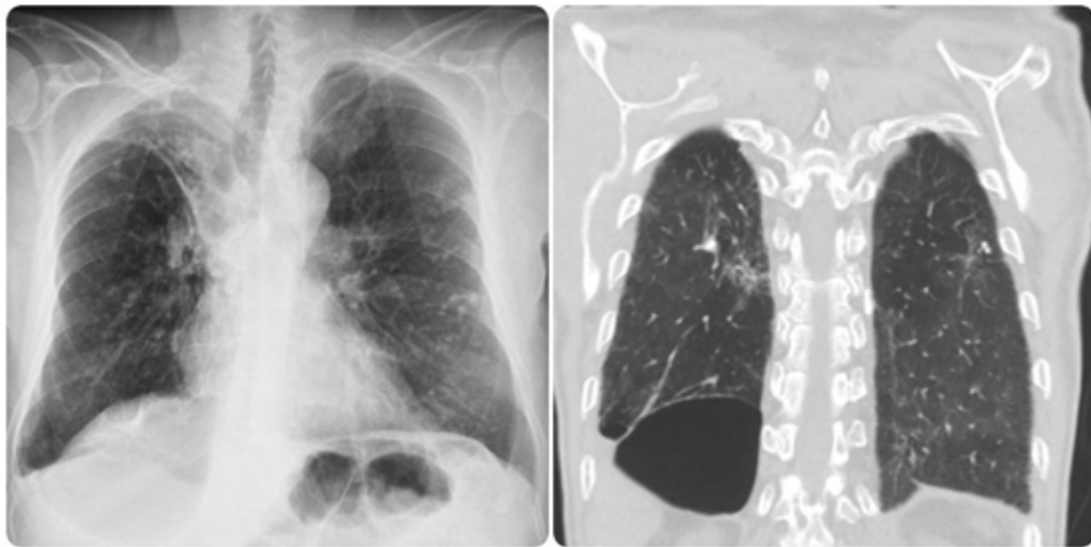
**Figure 2**

Examples of pulmonary air-containing lesions marked with yellow arrows on CT slices from patients in the present study population



**Figure 3**

The imaging of a patient who had the largest pulmonary air containing lesion; there is a posteroanterior chest X-ray on the left and a corresponding CT slice on the right



**PULMONARY BAROTRAUMA RISK FACTORS**

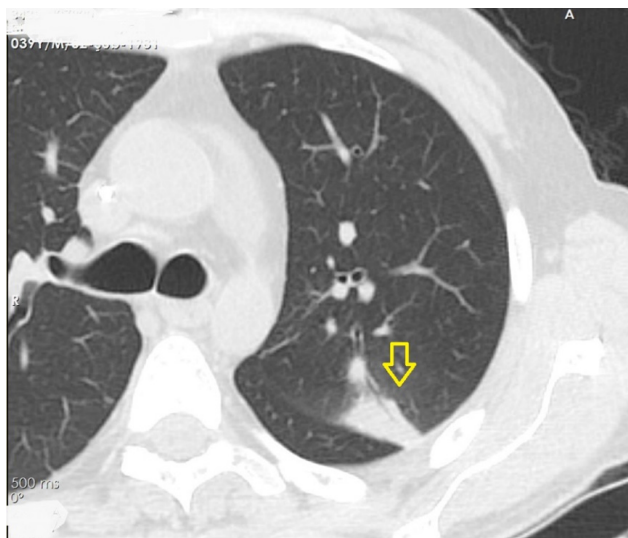
Among the five patients who underwent HBO treatment while intubated, one developed pneumothorax. Of the four patients with sarcoidosis who received treatment, one experienced dyspnoea. In a patient with restrictive spirometry findings, haemoptysis occurred. Apart from these cases, no PBT-related symptoms or signs were observed in

169 patients with PACL. Similarly, among nine patients with a history of pneumothorax, no PBT-related symptoms or signs were detected.

Among these, one patient continued HBO treatment while their pneumothorax was still present, with an indwelling chest tube. Another patient underwent HBO treatment after chest tube removal. The chest tube of this patient

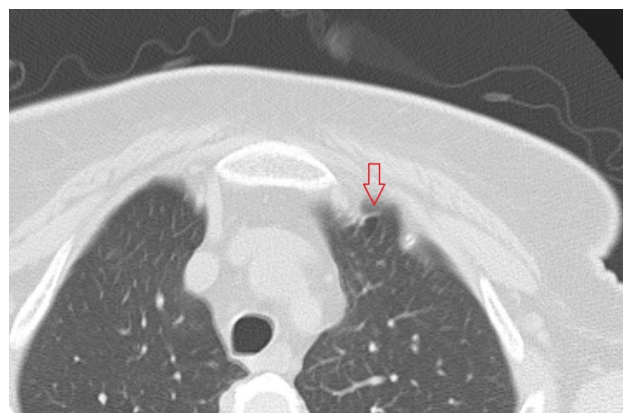
**Figure 4**

The CT slice of patient 116 with suspected pulmonary barotrauma, where the yellow arrow indicates the consolidated area



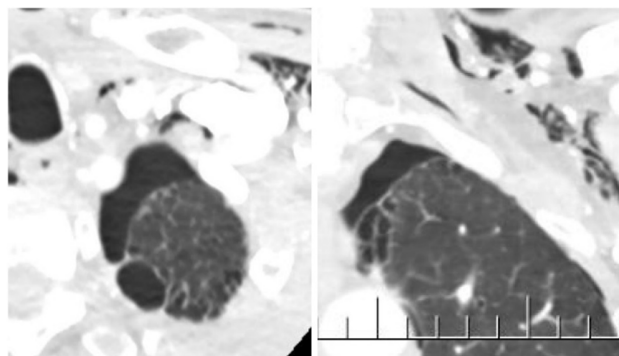
**Figure 5**

The CT slice of patient 613 with suspected pulmonary barotrauma, where the red arrow indicates a linear opacity increase surrounding the emphysema-like changes



**Figure 6**

The CT slices of patient with residual pleural air after cardiac surgery who was treated with HBO with the air present



was removed on postoperative day two following coronary artery bypass graft surgery. On postoperative day three, the patient developed central retinal artery occlusion, and HBO was initiated on postoperative day five. A CT angiogram of the head and neck performed two days prior to HBO treatment (Figure 6) revealed a persistent pneumothorax. The patient successfully completed 17 HBO sessions without complications. If the patient’s small pneumothorax did not resolve spontaneously within two days, then the patient received HBO treatment while the pneumothorax was still present. The reason it was not identified before HBO treatment was that a posteroanterior chest X-ray was obtained instead of an apicolordotic view, and it was not considered that the chest might be partially visualised in the head and neck CT angiography. The likely reason the pneumothorax did not worsen during treatment is that it was related to residual air following surgery, rather than air leaking from the pleura.

**SENSITIVITY AND SPECIFICITY**

The sensitivity of detailed pulmonary medical history, auscultation, and chest X-ray for PACL was determined to be 34%, while the specificity was 79%.

**PACL ETIOLOGY**

We analysed the relationship between PACL and conditions such as COPD, asthma, tuberculosis, collagen vascular diseases, sarcoidosis, pulmonary thromboembolism, interstitial lung disease, lung cancer and COVID-19 pneumonia. A significant association was identified between PACL and COPD ( $P < 0.001$ ), tuberculosis ( $P < 0.001$ ), lung cancer ( $P < 0.001$ ), collagen vascular diseases ( $P = 0.012$ ) and interstitial lung disease ( $P = 0.016$ ). When examining the relationship between PACL and smoking, we found that patients with a history of smoking more than 20 pack-years, current smokers, or those who had quit smoking less than 15 years ago had a significantly higher prevalence of PACL ( $P < 0.001$ ). In the study population, the prevalence of bullae and blebs was 22.4%; this rate was higher among smokers (42%) compared to non-smokers (16.6%).

**INTERRATER RELIABILITY**

In the analysis conducted between the two rating teams (OT/YA and MD), the agreement rate was 87%, the Cohen’s Kappa value was 0.72, and the  $P$ -value was  $< 0.0001$ .

**Discussion**

PBt during HBO is an extremely rare but serious complication. Although PACLs are theoretically considered to pose a risk for air trapping during changes in ambient pressure, our study demonstrated that these lesions were not observed to be associated with a measurable increased risk of PBt. The incidence of pneumothorax during HBO was found to be

extremely low (0.0059% per session and 0.15% per patient). The sensitivity of detailed pulmonary medical history, auscultation, and chest X-ray for PACL was determined to be 34%, while the specificity was 79%. We did not identify any conditions associated with PBt other than sarcoidosis and intubation.

Expanding alveolar gas can cause localised pulmonary injury and capillary haemorrhage without obvious signs of barotrauma such as pneumomediastinum or arterial gas embolism. Symptoms may include chest pain, cough, and haemoptysis, with supportive care usually being sufficient. However, a detailed neurological examination is essential to rule out subtle cerebral injury from a less apparent arterial gas embolism.<sup>7</sup> We therefore examined suspected PBt cases in detail, as their relatively mild clinical presentations may still conceal serious risks.

The main contributing factor to PBt is environmental pressure change (diving, HBO, flights). Normally, alveolar gas is expelled passively, but any obstruction to airflow can precipitate PBt. In diving PBt most commonly occurs at shallow depths because the proportional change in volume with pressure change is greatest in the shallow depth range.<sup>8</sup>

Another factor is mechanical ventilation and regulator systems, which can directly affect airway pressure. PBt can occur even in the absence of underlying air-trapping lesions in the lungs if the transpulmonary pressure exceeds the sustainable tissue pressure.<sup>9</sup> Transpulmonary pressures of approximately 9.47 to 10.93 kPa can cause alveolar rupture.<sup>10</sup> In a study by Örmeci et al., that measured regulator pressures, it was shown that during expiration, the air pressure inside an HBO mask could increase to 2.24 kPa, and up to 4.63 kPa during forced expiration.<sup>11</sup> Although this pressure increase is not high enough to directly cause alveolar rupture, it may lower the threshold for PBt. In hyperbaric environments, patients undergoing ventilation, especially during the decompression phase, face a risk of PBt if positive pressure exceeds 3.92 kPa;<sup>12</sup> in mechanically ventilated HBO, both airway pressure and ambient pressure vary. Toklu et al., reported PBt in two intubated patients among 98 HBO centres.<sup>8</sup> Bessereau et al., in their study involving 150 intubated patients undergoing HBO with a pneumatic ventilator, reported no pulmonary side effects other than patient-ventilator asynchrony.<sup>13</sup> Stahl et al., reported that airway pressure delivered by the ventilator decreases with increasing ambient pressure.<sup>14</sup> In cases where mechanical ventilation is applied in a normobaric environment, barotrauma is observed with a frequency of 4–15%.<sup>15</sup> In our study, no signs or symptoms were observed in the intubated patient who developed pneumothorax during the decompression phase, or after the HBO session. The onset of symptoms following the patient's transfer to the intensive care unit suggests that the pneumothorax may be related to manual ventilation (ambu-bagging) during transfer or to the mechanical ventilator used in the ICU.

Another factor is lesions that can cause air trapping in the lungs. Whether PACL lead to PBt depends on whether air can freely enter and exit these lesions. In bronchiectasis, the cysts communicate freely with the airways, whereas this is not necessarily the case for emphysema-like changes.<sup>16</sup> In a study by Morgan et al., only one out of 23 bullae contributed more than 10% to ventilation. The remaining 22 bullae either contributed minimally or, in some cases, not at all. Additionally, the volume of air within the bullae showed very little change during respiration.<sup>17</sup> In a study conducted by Pride et al., 13 out of 14 bullae (92%) contributed minimally or not at all to ventilation.<sup>18</sup> Sources on pathology state that bullae are in free communication with the underlying lung parenchyma; however, it is important to note that these tests were conducted *in vivo*.<sup>19</sup> Most bullae are poorly ventilated, a minority are either well ventilated or not ventilated at all.

These three issues should be discussed together. When air exchange in PACL is weak, the bulla will take in air to equalise its internal pressure with the surrounding pressure as ambient pressure increases. Conversely, as ambient pressure decreases, the bulla will release air to balance the increased internal pressure. If the pressure change occurs too quickly for the air to exit, the air inside the bulla will expand, and PBt will occur once the pressure exceeds the sustainable tissue pressure.

When PACL are well ventilated, the risk of PBt will be low due to effective air exchange. If there is no air exchange in the PACL, the size of the lesions will decrease with pressure increases (HBO compression phase) and return to their original size as pressure decreases (HBO decompression phase), in accordance with Boyle's Law. In this case, PACL will not pose a high risk for PBt, except in hypobaric environments such as air travel.<sup>20,21</sup>

In our study, among the 169 patients with PACL, 1.1% ( $n = 2$ ) were suspected of having PBt, but no pneumothorax was observed. Although these lesions were not observed to be associated with an increased risk of PBt, it is important to acknowledge existing case reports and case series suggesting an elevated risk, warranting a careful, informed consent-based discussion with patients who have pulmonary pathology.<sup>22,23</sup> Although the aeration in emphysema-like changes was weak, it was considered sufficient to accommodate changes in transpulmonary pressure. In other words, the transpulmonary pressure generated allowed air to escape without exceeding sustainable tissue pressure. Although the high altitude of our department (938 m, Ankara) theoretically increases the risk of PBt, the fact that many patients with PACL have been successfully treated without complications suggests that the disease carries a lower risk of PBt at altitude than previously thought. Indeed, in the survey conducted by Toklu et al., it was reported that 66% of HBO centres have admitted patients with bullous lesions for treatment,<sup>8</sup> and our study has supported the approach of these centers.

Brenna et al., reported one case of PBt in their single-centre experience involving 2,250 patients and 62,040 HBO sessions. They documented a PBt incidence of 0.0016% per session or 0.044% per patient.<sup>24</sup> Similarly, in a survey study by Toklu et al., encompassing approximately two million sessions across 98 centers, nine cases of PBt were reported in seven centres, with a session-based PBt incidence of 0.00045%.<sup>8</sup> In our study, the PBt incidence was 0.0059% per session and 0.15% per patient. Assuming that chest CT imaging was also performed to detect lung diseases, we can say that the higher incidence in our study compared to other studies is due to our focus on the patient group with chest CT imaging.

There are various concerns regarding the sensitivity of chest radiography in detecting PACL. The sensitivity of chest radiography for moderate to severe emphysema is 41%.<sup>25</sup> In the study by Wingelaar et al., the sensitivity of chest radiography for bullous lesions was 0%, and the specificity was 90%.<sup>26</sup> In emphysema-like changes, lung CT has a sensitivity of 84% and a specificity of 100%.<sup>27</sup> In our study, the sensitivity of a detailed pulmonary medical history, auscultation, and chest X-ray for detecting PACL was found to be 34%, while the specificity was 79%. This highlights the use of chest CT in respiratory system screenings prior to HBO treatment or diving. However, due to radiation exposure, cost, limited availability, and potential for overdiagnosis, CT is not always feasible for routine screening. This situation raises questions about the adequacy of screening patients using only auscultation and chest radiography, particularly for identifying air-trapping lesions that may lead to PBt. While evidence remains insufficient regarding the effectiveness of chest radiographs in detecting such lesions, the role of advanced imaging techniques like CT has become more prominent in recent debates about PACL screening during fitness-to-dive and pre-HBO treatment examinations.

When reviewing studies on the frequency of bullous lesions, the prevalence in the general population ranges from 4.7% to 33.8%.<sup>28–30</sup> In the diver population, it ranges from 1.9% to 7.8%.<sup>26,31,32</sup> In our study, the prevalence of bullous lesions was 22.4%, which was higher than in five of the six studies mentioned above. This may be explained by the retrospective nature of our study, in which the chest CT scans were performed on selected risk groups for pulmonary disease screening.

Brenna et al., identified some low-risk factors for PBt, including the absence of findings, symptoms, or history of conditions such as COPD, asthma, pulmonary fibrosis, sarcoidosis, pneumothorax, and acute respiratory distress syndrome.<sup>24</sup> In our study, apart from intubation and sarcoidosis, we did not identify any other associated conditions. We also could not determine any relationship between PBt and PACL or a history of pneumothorax.

The first limitation of our study is that, for some patients, follow-up CT scans were not performed in close temporal proximity to their HBO treatment. The second limitation is the retrospective design of the study, which may have resulted in incomplete data collection. Additionally, only patients treated at our centre were included; therefore, the generalisability of our findings is limited. However, the inclusion of a large cohort from a single center can also be considered a strength of the study.

## Conclusions

PBt during HBO treatment remains an extremely rare complication. Our findings suggest that PACL, including bullae, were not observed to be associated with an increased risk of PBt under standard HBO protocols. The slow and controlled decompression profile of HBO likely mitigates the risk, even in the presence of PACL. Although chest CT remains the most sensitive tool for identifying such lesions, its routine use in screening may not be justified given the low incidence of complications. Careful clinical evaluation, including detailed history and physical examination, remains essential. Patients with underlying pulmonary disease should be appropriately counselled, and informed consent obtained. Further prospective studies are warranted to refine risk stratification and screening strategies for HBO candidates.

## References

- 1 Heyboer M 3rd, Santiago W. Side effects of hyperbaric oxygen therapy. In: Huang E, editor. UHMS hyperbaric medicine indications manual. North Palm Beach (FL): Best Publishing; 2024. p. 361.
- 2 Hansell DM, Bankier AA, MacMahon H, McLoud TC, Müller NL, Remy J. Fleischner Society: glossary of terms for thoracic imaging. *Radiology*. 2008;246:697–722. doi: [10.1148/radiol.2462070712](https://doi.org/10.1148/radiol.2462070712). PMID: [18195376](https://pubmed.ncbi.nlm.nih.gov/18195376/).
- 3 Singla A, McCormack FX. Definition and classification of diffuse cystic lung diseases. In: Gupta N, Wikenheiser-Brokamp KA, McCormack FX, editors. Diffuse cystic lung diseases. Cham: Humana; 2021. p. 1–19. doi: [10.1007/978-3-030-63365-3\\_1](https://doi.org/10.1007/978-3-030-63365-3_1).
- 4 Huda W, Slone RM. Computed tomography. In: Huda W, Slone RM. Review of radiologic physics. Philadelphia (PA): Lippincott Williams & Wilkins; 2003. p. 74.
- 5 Rosenblum LJ, Mauceri RA, Wellenstein DE, Thomas FD, Bassano DA, Raasch BN, et al. Density patterns in the normal lung as determined by computed tomography. *Radiology*. 1980;137:409–16. doi: [10.1148/radiology.137.2.7433674](https://doi.org/10.1148/radiology.137.2.7433674). PMID: [7433674](https://pubmed.ncbi.nlm.nih.gov/7433674/).
- 6 Gevenois PA, de Maertelaer V, De Vuyst P, Zanen J, Yernault JC. Comparison of computed density and macroscopic morphometry in pulmonary emphysema. *Am J Respir Crit Care Med*. 1995;152:653–7. doi: [10.1164/ajrccm.152.2.7633722](https://doi.org/10.1164/ajrccm.152.2.7633722). PMID: [7633722](https://pubmed.ncbi.nlm.nih.gov/7633722/).
- 7 Van Hoesen K, Neuman TS. Venous and arterial gas embolism. In: Neuman TS, Thom SR, editors. Physiology and medicine of hyperbaric oxygen therapy. Philadelphia (PA): Saunders; 2008. p. 263.
- 8 Toklu AS, Korpınar S, Erelel M, Uzun G, Yildiz S. Are pulmonary bleb and bullae a contraindication for hyperbaric

